



Journal of Coloproctology

www.jcol.org.br



Case Report

Coloanal intussusception in adults due to lipoma

Luciano Dias de Oliveira Reis*, João Roberto Matos, Paula Nicoli Soares,
Luiz Henrique Bastos Mendes, Cassiana Franco Dias dos Reis,
Celso Augusto Milani Cardoso Filho, Orlando Papi Fernandes, Alex P. Costa

Hospital Nossa Senhora da Saúde, Santo Antônio da Platina, PR, Brazil

ARTICLE INFO

Article history:

Received 13 March 2018

Accepted 1 May 2018

Available online 22 May 2018

Keywords:

Colonic lipoma

Coloanal intussusception

Colo-anal invagination

ABSTRACT

Adult intussusception is a rare condition. But coloanal intussusception is an exception. Malignant lesions are the most common cause of colonic intussusception, and in this aspect, differ from childhood intussusception. We present a case wherein the patient had a lipoma of the sigmoid colon that caused an immense prolapse through the anus. Very few cases of coloanal intussusception are reported in adults, and we discuss the diagnostic tools and the management of this rare surgical entity.

© 2018 Sociedade Brasileira de Coloproctologia. Published by Elsevier Editora Ltda. This is an open access article under the CC BY-NC-ND license (<http://creativecommons.org/licenses/by-nc-nd/4.0/>).

Intussuscepção colo-anal decorrente de lipoma em adulto

RESUMO

A intussuscepção no adulto é uma entidade rara. Mas a intussuscepção colo-anal é uma exceção. Lesões malignas são a causa mais comum de intussuscepção colônica e, neste aspecto, difere da intussuscepção infantil. Apresentamos um caso de lipoma do cólon sigmoide que causou um prolapso imenso através do ânus. Muito poucos casos de intussuscepção colo-anal foram relatados em adultos e discutimos as ferramentas diagnósticas e o tratamento dessa entidade cirúrgica rara.

© 2018 Sociedade Brasileira de Coloproctologia. Publicado por Elsevier Editora Ltda. Este é um artigo Open Access sob uma licença CC BY-NC-ND (<http://creativecommons.org/licenses/by-nc-nd/4.0/>).

Palavras-chave:

Lipoma colônico

Intussuscepção colo-anal

Invaginação colo-anal

Introduction

Intussusception is defined as the telescoping of one segment of the gastrointestinal tract into an adjacent one.¹ It is common in children mainly in the first year of age. In contrast to

childhood intussusception, which is idiopathic in 90% of the cases, in adults, the majority of cases are due to malignant or benign tumors.^{2,3}

Adult intussusception may present as chronic intermittent intestinal obstruction⁴ or as acute abdomen. It very rarely presents as a prolapsed colon protruding through the anus. According to Lateste, by 1975, only 6 cases of coloanal invagination had been reported.⁵

Adult colonic intussusception should be managed with resection without reduction.¹ But initial reduction of the

* Corresponding author.

E-mail: reisluciano@uol.com.br (L.D. Reis).

<https://doi.org/10.1016/j.jcol.2018.05.002>

2237-9363/© 2018 Sociedade Brasileira de Coloproctologia. Published by Elsevier Editora Ltda. This is an open access article under the CC BY-NC-ND license (<http://creativecommons.org/licenses/by-nc-nd/4.0/>).

coloanal intussusception should be attempted before resection⁵ with the intention to preserve anal sphincter function. In our case we could see the lipoma ahead of the invaginated ischemic and edematous colon that was reduced with difficulty before surgical resection.

Case report

GD, a 60-year-old Caucasian male, started complaining of intermittent abdominal pain 4 days before hospitalization. During this period, he went twice to the emergency room, and he was sent home after receiving analgesics. He reported that when his bowel was protruding from his anus, it spontaneously returned to its anatomic site before being seen by the doctor, and so this information was not taken into account. The following day, another doctor performed a digital examination and felt the presence of a mass and thought it to be a tumor; therefore, the patient was admitted to hospital. Next day, a rectal examination was done and a smooth mass was noted in the anorectal junction, which was recorded by CT scan (Fig. 1).

A colonoscopy was planned, but before that could be performed, a rectal prolapse with a round mass at its apex was seen and registered by the staff (Fig. 2).

We suspected lipoma of the colon because we had a similar case in the past.⁴ Meanwhile, the intussusception progressed with a larger portion of the colon and rectum with increased edema and ischemia of the prolapsed segment (Fig. 3).

We reduced the colorectal segment with difficulty and an immediate rigid retosigmoidoscopy was performed. Surgery was planned after a prompt CT scan demonstrated the presence of air in the mesorectum and severe edema of the rectum and sigmoid and a lipoma of the sigmoid (Figs. 4 and 5).

During operation, we found an ischemic sigmoid colon and a round mass, previously reported as a lipoma, which were easily detected by touch. A partial colectomy and colostomy (Hartmann procedure) was undertaken including the lipoma and an ischemic segment of the colon (Fig. 6).

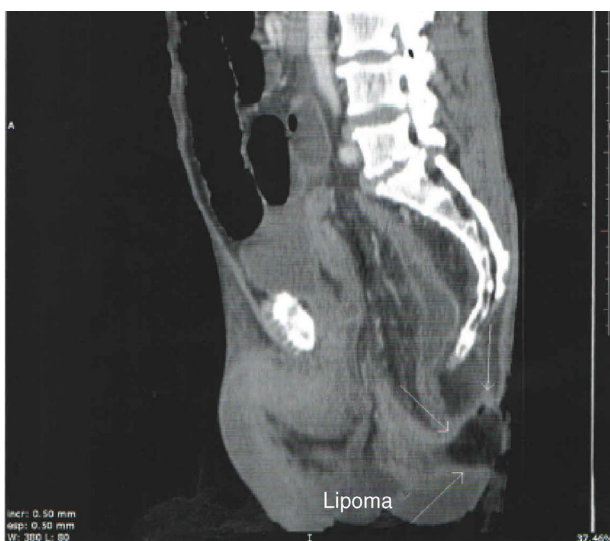


Fig. 1 – Lipoma as leading point for intussusception at anal verge.

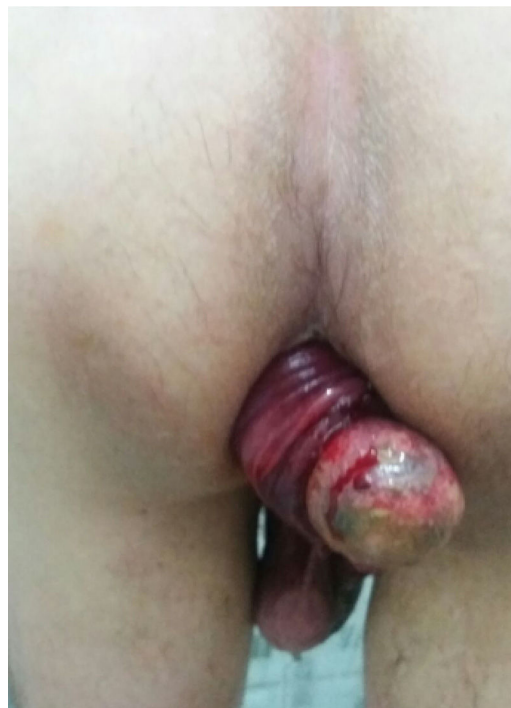


Fig. 2 – Rectal prolapse with a round mass at its apex.

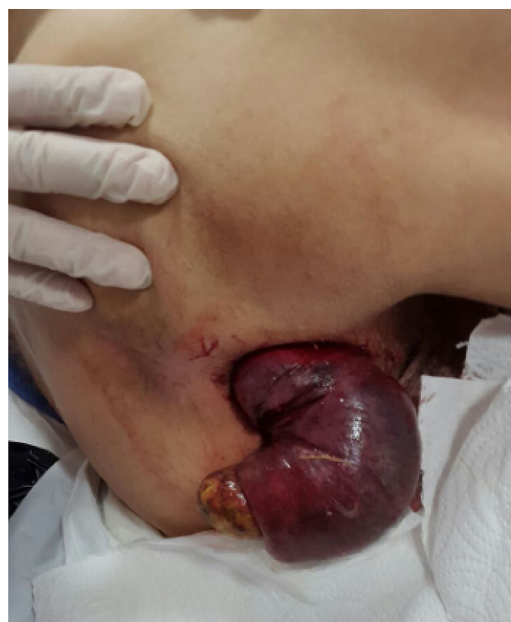

Fig. 3 – Prolapsed ischemic intussusceptions.

The patient recovered rapidly. After 4 months, the patient was readmitted for colorectal anastomosis and is currently doing well.

Discussion

Adult intussusception is a rare condition with many surgeons encountering only one or two cases throughout their career. Reported incidence in adults is 2 to 3 cases in a population

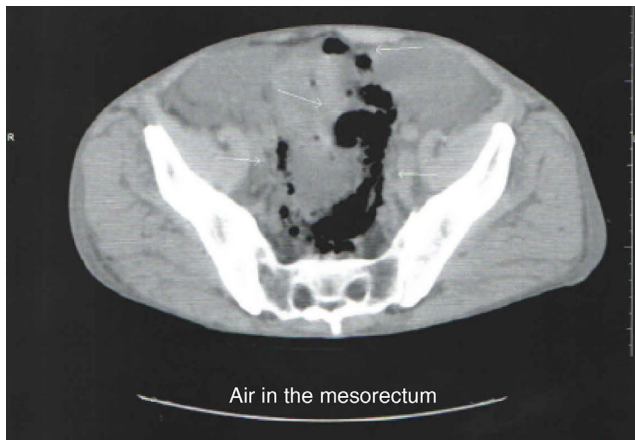


Fig. 4 – CT scan demonstrated the presence of air in the mesorectum.

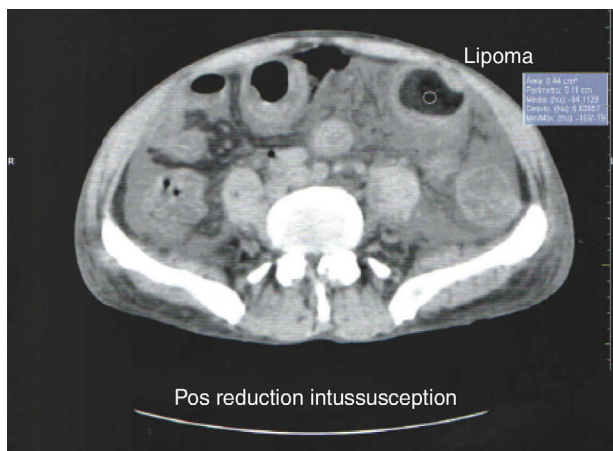


Fig. 5 – CT scan demonstrated the presence of severe edema and a lipoma of the sigmoid.

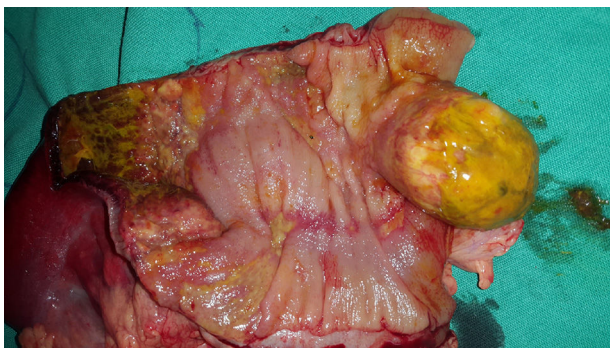

Fig. 6 – A partial colectomy and colostomy (Hartmann procedure).

of 1,000,000 per annum.⁶ Intussusception occurs when one loop of the bowel (Intussusceptum) telescopes into adjacent segment (Intussusciens).⁷ Intussusception is more common in children when 90% are idiopathic but in adults an underlying pathological lead point is found in 90% of cases. Intussusception in adults is more common in the small bowel. In the colon, it is more frequent on the right side. Coloanal

intussusceptions are rare and usually occur in the setting of a benign or malignant tumor.⁸⁻¹⁰

Presenting symptoms of intussusception in adults are non-specific. Pain is the commonest symptom, being reported in 71–90% of the patients. The pain may be indolent and frequently intermittent and is related to the size of the tumor.^{4,7,10} Vomiting and bleeding through the rectum are the next most common symptoms. Intestinal obstruction occurs infrequently, and the diagnosis made during laparotomy.¹⁰ Cases of coloanal intussusception in adults where the invaginated colon can be detected by touch during a rectal digital examination has been reported, but colonic intussusception with the lead lesion heading the protruded colon makes the diagnosis very easy.

According to Azar et al., colocolonic intussusception should be treated with resection without attempting reduction because almost 50% of the cases are malignant.¹

Coloanal intussusception may be reduced for a later resection,⁸ and it is possible by barium enema, wherein gently manual compression of the colon occurs, which may be followed by rigid retosigmoidoscopy to examine the mucosa and to ratify the reduction (as in our case). If the cause of the intussusception is a pediculated lesion, it may be locally resected before manual reduction of the colon.^{11,12}

Computed tomography seems to be the most reliable investigation method for making a preoperative diagnosis.^{1,13} In our case, a CT scan was ordered before and after the reduction of the intussusception in order to help to precisely locate the lipoma and to reinforce the decision to perform immediate laparotomy.

Conclusion

Rarely colonic intussusception can present as prolapse through the anus in an adult and should be investigated before definitive treatment. CT scan is the investigation of choice. Initial reduction of the colorectal intussusception should be attempted before surgery to preserve sphincter function.⁷

Conflicts of interest

The authors declare no conflicts of interest.

REFERENCES

1. Azar T, Berger DL. Adult intussusception. *Ann Surg.* 1981;193:130–6.
2. Garg P, Garg G, Verma S, Mittal S, Rathee VS, Narang A, et al. Adult intussusception: case series. *IJRRMS.* 2012;2:36–40.
3. Toms N, Bicknell C, Harrison R. Colo-anal intussusception in an adult: case report and review of the literature. *Int J Clin Pract.* 2009;63:175–6.
4. Reis LDO, Mendes LHB, Cardoso Filho CAM, Reis ADO, Arruda JAM. Intussuscepção intermitente de lipoma de colon transverso. *Rev Bras Coloproct.* 2006;26:447–8.
5. Lataste J, Albou JC, Boeuf A. Colo-anal invagination in adults. *J Chir.* 1975;109:489–94.
6. Carter CR, Morton AL. Adult intussusception in Glasgow, UK. *Br J Surg.* 1989;76:727.

7. Hg V, Vora HB, Bhavsar MS. Sigmoidorectal intussusception presenting as prolapse per anus in an adult. *World J Colorectal Surg.* 2013;3, art 3.
8. Bail JP, Holderbach LJ, Robaszkiewicz M, Dartoy C, Noundou PM, Charles JF. Primary colonic intussusception protruding from the anus in the adult. Two cases. *Ann Radiol.* 1992;35:249-54.
9. Toms N, Bicknell C, Harrison R. Colo-anal intussusception in an adult: case report and review of the literature. *Into J Clan Pact.* 2009;63:175-6.
10. Yalamarathi S, Smith RC. Adult Intussusception: case reports and review of literature. *Postgrad Med J.* 2005;81:174-7.
11. Guerra GMLSR, Souza HFS, Fonseca MFM, Codes LMG, Albuquerque IC, Formiga GJS. Intussuscepção colo-cólica exteriorizada pelo ânus, secundária a lipoma – Relato de caso. *Rev Bras Coloproct.* 2005;25:382-5.
12. Lyra G, Coutinho RPCR, Leal RC. Lipoma colônico mimetizando pólipos gigante parido – relato de caso. *Rev Bras Coloproct.* 2004;24:63-4.
13. Gayer G, Apter S, Hofmann C, Nass S, Amitral M, Zissin R, et al. Intussusception in adults: CT diagnosis. *Clin Radiol.* 1998;53:53-7.