



Journal of Coloproctology

www.jcol.org.br



Original Article

Effects of hydroalcoholic extract of *Ziziphus jujuba* on acetic acid induced ulcerative colitis in male rat (*Rattus norvegicus*)



Nader Tanideh^{a,b}, Akram Jamshidzadeh^c, Ali Ghanbari Saghesloo^{c,*}, Farhad Rahmanifar^d, Maral Mokhtari^e, Omid Koochi-Hosseini^f, Mahmood Omid^c, Asma Najibi^c

^a Shiraz University of Medical Sciences, Stem Cell and Transgenic Technology Research Center, Shiraz, Iran

^b Shiraz University of Medical Sciences, School of Medicine, Department of Pharmacology, Shiraz, Iran

^c Shiraz University of Medical Sciences, School of Pharmacy, Department of Pharmacology Toxicology, Shiraz, Iran

^d Shiraz University, School of Veterinary Medicine, Department of Anatomy, Shiraz, Iran

^e Shiraz University of Medical Sciences, School of Medicine, Department of Pathology, Shiraz, Iran

^f Shiraz University of Medical Sciences, Center of Comparative and Experimental Medicine, Shiraz, Iran

ARTICLE INFO

Article history:

Received 1 March 2016

Accepted 20 April 2016

Available online 27 May 2016

Keywords:

Ziziphus jujuba

Ulcerative colitis

Oxidative stress

Histopathology

Inflammation

ABSTRACT

Objective: To investigate the effects of hydroalcoholic extract of *Ziziphus jujuba* on the histopathological, tissue oxidative stress and inflammation plus to antioxidant pathways of colon tissue in rat with induced Ulcerative colitis.

Materials and methods: Ulcerative colitis was induced in 80 rats those divided into 8 equal groups. Group 1 and 2 were negative controls receiving 1 mL/day of normal saline in enema and oral; group 3 and 4 as positive control 1 and 2 received 10 mg/kg of intra-colonic asacol and oral mesalazine; groups 5 and 6 received 20% and 40% of hydroalcoholic extract of *Z. jujuba* trans-rectally; group 7 and 8 received 1500 and 3000 mg/kg of hydroalcoholic extract of *Z. jujuba* orally, respectively. After 7 days, animals were evaluated for colon tissue histopathology, levels of malondialdehyde and IL-1 β , and activities of superoxide dismutase, glutathione peroxidase and myeloperoxidase in colon tissue.

Results: Hydroalcoholic extract of *Z. jujuba* in both forms of trans-rectal and oral administration especially in the higher doses could result into a more healing effect in damaged colonic tissue, more reduce glutathione peroxidase and IL-1 β level. Also, these two doses (gel 40% and oral 3000 mg/kg) could more decrease the myeloperoxidase activity and stimulate superoxide dismutase and glutathione peroxidase activities. Also, gel 40% in transrectal administration was more potent than administration 3000 mg/kg in oral.

* Corresponding author.

E-mail: articlepublishers93@gmail.com (A. Ghanbari Saghesloo).

<http://dx.doi.org/10.1016/j.jcol.2016.04.007>

2237-9363/© 2016 Published by Elsevier Editora Ltda. on behalf of Sociedade Brasileira de Coloproctologia. This is an open access article under the CC BY-NC-ND license (<http://creativecommons.org/licenses/by-nc-nd/4.0/>).

Conclusion: The results of the present study indicated that *Z. jujube* may be considered as a treatment of choice for Ulcerative colitis especially in gel form and also in dose-dependent pattern.

© 2016 Published by Elsevier Editora Ltda. on behalf of Sociedade Brasileira de Coloproctologia. This is an open access article under the CC BY-NC-ND license (<http://creativecommons.org/licenses/by-nc-nd/4.0/>).

Efeitos do extrato hidroalcoólico de *Ziziphus jujuba* na colite ulcerativa induzida pelo ácido acético em rato macho (*Rattus norvegicus*)

R E S U M O

Palavras-chave:

Ziziphus jujuba
Colite ulcerativa
Estresse oxidativo
Histopatologia
Inflamação

Objetivo: Investigar os efeitos do extrato hidroalcoólico de *Ziziphus jujuba* no estresse oxidativo em tecido ao nível histopatológico e na inflamação, juntamente com as vias antioxidantes em tecido de cólon em ratos com colite ulcerativa induzida.

Materiais e métodos: Induzimos colite ulcerativa em 80 ratos, divididos em 8 grupos iguais. Os grupos 1 e 2 eram controles negativos que receberam 1 mL/dia de salina normal em enema e por via oral; os grupos 3 e 4 eram controles positivos para 1 e 2 e receberam 10 mg/kg de asacol por via intracolônica e mesalazina oral; os grupos 5 e 6 receberam gel a 20% e 40% de extrato hidroalcoólico de *Z. jujuba* por via trans-retal; os grupos 7 e 8 receberam 1500 e 3000 mg/kg de extrato hidroalcoólico de *Z. jujuba* por via oral, respectivamente. Transcorridos 7 dias, os animais foram avaliados para histopatologia de tecido de cólon, níveis de malonildialdeído e IL-1 β , e atividades de superóxido dismutase, glutatión peroxidase e mieloperoxidase no tecido colônico.

Resultados: O uso do extrato hidroalcoólico de *Z. jujuba*, tanto na forma transretal como oral, e em especial nas doses mais altas, resultou em um efeito de cicatrização mais intensa no tecido colônico lesionado, e em maior redução nos níveis de glutatión peroxidase IL-1 β . Além disso, essas duas doses (gel a 40% e 3000 mg/kg por via oral) diminuíram ainda mais a atividade de mieloperoxidase e estimularam as atividades de superóxido dismutase e glutatión peroxidase. Outro achado do estudo foi que o gel a 40% por administração trans-retal se mostrou mais potente do que a administração oral de 3000 mg/kg.

Conclusão: Os resultados do presente estudo sugerem que *Z. jujuba* pode ser considerado como tratamento de escolha para colite ulcerativa, sobretudo em forma de gel e também em um padrão proporcional à dose administrada.

© 2016 Publicado por Elsevier Editora Ltda. em nome de Sociedade Brasileira de Coloproctologia. Este é um artigo Open Access sob uma licença CC BY-NC-ND (<http://creativecommons.org/licenses/by-nc-nd/4.0/>).

Introduction

Inflammatory bowel diseases (IBDs) include two parts, ulcerative colitis (UC) and Crohn's disease (CD). UC affected the superficial layer of all parts of the large intestine specially descending colon and rectum.¹ Incidence of UC is 1.2–20.3 cases and its prevalence is 7.6–240 cases per 100 000 peoples in each year.² The basis of the UC is genetically susceptibility to inflammation and also environmental triggers.³ These environmental factors include microbiological,^{4,5} immunological,⁶ smoking and psychological factors.⁵ So, some treatments can be applicable to overcome these environmental factors. In addition, besides the cost of treatment, the impact of UC on quality of life is staggering.⁷ Therefore, finding effective and cost benefit treatment for UC is necessary.

Before each study for finding good therapeutic agents for UC, it is necessary to simulate the conditions similar to human UC in animal models. There are several models for induction of UC in animals such as use of trinitrobenzene sulfonic

acid (TNBS) (7), dextran sodium sulfate,⁸ and acetic acid.⁹ Rectal administration of acetic acid can mimic the conditions which occurred in human UC¹⁰ and related UC is a reproducible laboratory animal model and is useful for screening of effectiveness of drugs.¹¹

Use of medicinal plants and their derivatives has an ancient basis. *Ziziphus jujube* is a herbal plant belongs to the Rhamnaceae family and is one of the most important *Ziziphus* species.¹² The jujube fruit contains many bioactive compounds, including triterpenic acids, flavonoids, cerebrosides, phenolic acids, α -tocopherol, β -carotene, and polysaccharides. Each constituent of the jujube presents some health benefits, thus making it a healthy food choice and also as therapeutic agent.¹³ The beneficial effects of administration of *Z. jujuba* as alternative treatment in oral mucositis (OM) has been reported previously.¹⁴ The objective of present investigation was to evaluate the therapeutic effects of hydroalcoholic extract of *Z. jujuba* in experimentally induced UC in male rat as an animal model for human studies.

Materials and methods

Ethical statement

The protocol of the presented study is approved by the Ethical Committee of Shiraz University of Medical Sciences. All efforts were made to prevent the harmful handling of the animals and also the lowest but statistically significant number of the animals was allocated in each group.

Fruit and extraction

Z. jujuba fruits were purchased from local market and after genus and species confirmation by Botanist affiliated to Agriculture School of Shiraz University, were finely grounded by mixer. The hydroalcoholic extraction was performed according to previous report.¹⁵ The antioxidant content of this extract was evaluated using ferric reducing antioxidant power (FRAP) test as described previously.¹⁶

Animals

In this study, 80 male Sprague Dawley rats with mean and SD of weigh of 200 ± 20 g were purchased from the Center of Comparative and Experimental Medicine, Shiraz University of Medical Sciences. They kept under conventional conditions include 22 ± 1 °C, $55 \pm 5\%$ relative humidity, and 12/12 h light/dark cycles before the onset of the study for acclimation and during the study period. All rats were fasted for 24 h and then UC was induced by rectal administration of 1 mL of 3% acetic acid. Animals were randomly allocated into 8 equal separated groups and received different treatment after 24 h, based on the Table 1.

At the end of the 7th day, all rats were sacrificed by cervical dislocation and samples from colon tissue were obtained

and fixed in 10% buffered formalin. The tissue processing and histopathological slide preparation were performed according to previous procedures.^{17–19} The histopathological sections were evaluated for severity and extent of inflammation, crypt damage, percent of involvement and regeneration.

Measurement of malondialdehyde (MDA) level

Briefly, 500 mg of tissue was homogenized in 5 mL of 1.15% cold KCl. Then, 3 mL of 1% phosphoric acid and 1 mL of 0.6% tiobarbitoric acid were added to 500 μ l of homogenate and shake well. After indirect heating at 100 °C for 45 min, the centrifugation was performed at 10 000 rpm for 10 min and the absorbance of the supernatant was measured in 532 nm using UV-visible spectrophotometer.

Myeloperoxidase (MPO) activity

Two mL of phosphate buffer contain 0.5% hexadecyl trimethyl ammonium bromide (HTAB) was added to 100 mg of colon tissue and homogenized on ice for six times of 45 s. Then, 10 s of sonication and freeze by liquid nitrogen were applied for three times. Centrifugation at 3000 rpm and 4 °C for 30 min was performed and supernatant was harvested. 2.9 mL of phosphate buffer contain o-Dianisidine and 0.005% hydrogen peroxide was added to 0.1 mL of supernatant and after 5 min, 0.1 mL of 1.2M HCl was added to tube to orange color was appeared. The absorbance of the samples was measured at 460 nm by UV-visible spectrophotometer and the activity of MPO was calculated using a standard curve.

Superoxide dismutase (SOD) and glutathione peroxidase (GPx) activities

The activities of these two antioxidative enzymes were assessed using commercial kits (Biorexfars, Iran).

Interleukin (IL)-1 β

The colon tissue content of IL-1 β determined by commercial quantities enzyme linked immunosorbent assay (ELISA) kit (Biosource, USA) according to the manufacturer instruction.

Statistical analysis

Data were expressed as mean and SD and analyzed using SPSS version 21. One way analysis of variance (ANOVA) with using Tukey as Posthoc test were used to find statistical significant differences ($p < 0.05$). GraphPad 6 was used for drawing the charts.

Results

Evaluation of damage and regeneration in the colon tissue showed that the severity and extent of inflammation, crypt damage, percent of involvement and regeneration in NC1 and NC2 were significantly higher than all other groups ($p < 0.05$) but not statistically significant together ($p > 0.05$). No significant differences were detected between other 6 groups in

Table 1 – Experimental setup and treatments which used in this study.

Group no.	Abbreviation	Treatment
1	Negative control 1 (NC1)	1 mL normal saline, enema
2	Negative control 2 (NC2)	1 mL normal saline, oral
3	Positive control 1 (PC1)	Asacol 10 mg/kg, enema
4	Positive control 2 (PC2)	Mesalazine 10 mg/kg, oral
5	Gel 20%	1 mL of gel 20% of ZJHE, enema
6	Gel 40%	1 mL of gel 40% of ZJHE, enema
7	Oral 1500	1 mL of solution of ZJHE as dose 1500 mg/kg, oral
8	Oral 3000	1 mL of solution of ZJHE as dose 3000 mg/kg, oral

ZJHE, *Z. jujuba* hydroalcoholic extract.

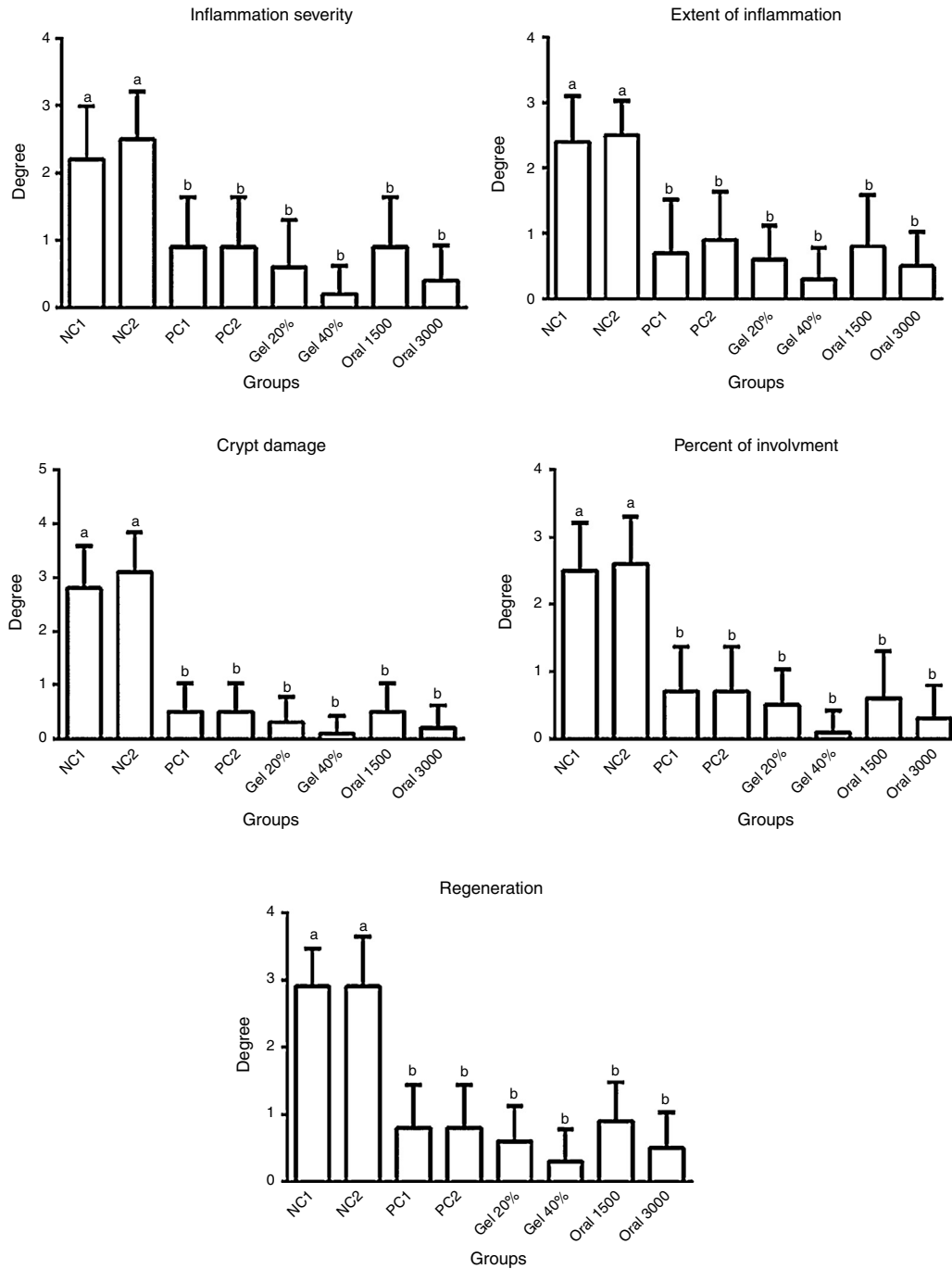


Fig. 1 – Comparison of histopathological indices of damage and regeneration between different groups. Significant statistical differences between groups in each index are indicated by different superscript letter ($p < 0.05$).

all pathological indices include inflammation severity and extent, crypt damage, percentage of involvement and regeneration ($p > 0.05$) (Fig. 1).

Comparison of MDA level as oxidative stress index and activities of two antioxidative enzymes, SOD and GPx, in colon tissue are presented in Fig. 2. As shown, the colon tissue MDA concentration in NC1 and NC2 were significantly higher than all other groups ($p < 0.05$) but not statistically significant together ($p > 0.05$). The tissue MDA concentration

in gel 20% was significantly higher than gel 40% and oral 3000 groups and significantly lower than all other groups ($p < 0.05$). Despite of the NC1 and NC2, the MDA level in oral 1500 group was significantly higher than all other groups ($p < 0.05$) but not significantly differ with PC2 ($1.85 \pm 0.04 \mu\text{mol/L}$ vs. $1.83 \pm 0.06 \mu\text{mol/L}$, $p > 0.05$). Lowest MDA level was detected in gel 40% group ($0.86 \pm 0.03 \mu\text{mol/L}$) followed by oral 3000 group ($1.07 \pm 0.04 \mu\text{mol/L}$) (Fig. 2A). Changes in the activities of both SOD and GPx showed approximately similar pattern.

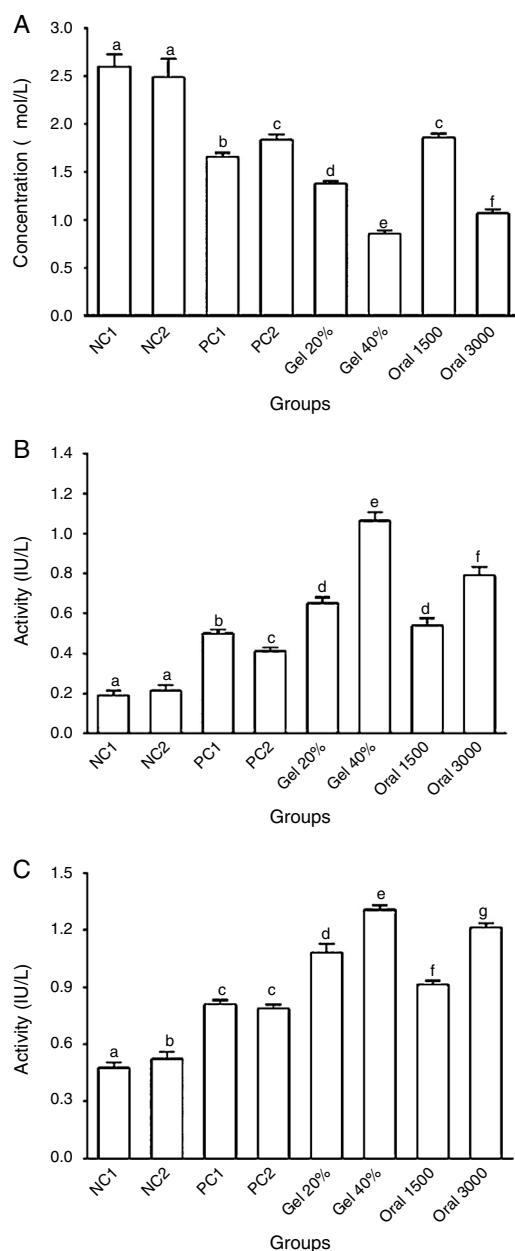


Fig. 2 – Comparison of mean and SD of A, malondialdehyde level; B, glutathione peroxidase activity and C, superoxidase dismutase activity in colon tissues of different experimental groups. Significant statistical differences between groups in each index are indicated by different superscript letter ($p < 0.05$).

This included higher activities of enzymes in all groups in comparison to both NC groups, highest and lowest activities of both enzymes between treatment group in gel 40% and PC2, respectively, and highest activities of both enzyme in response to oral mesalazine in comparison to enema asacol. Other differences and their significances are shown in Fig. 2B and C.

Comparison of inflammatory biomarkers of IL-1 β and MPO activity in colon tissue of different groups are presented in Fig. 3. As shown, these two inflammatory indices were

decreased in response to treatments in comparison to both NC groups ($p < 0.05$). The most declines were belonged to the gel 40% group (210.00 ± 22.47 pg/mL for IL-1 β and 1.19 ± 0.05 IU/L for MPO) followed by oral 3000 group (318.20 ± 31.49 pg/mL for IL-1 β and 1.37 ± 0.03 IU/L for MPO). Other values and their significances can be seen in Fig. 3A and B.

Discussion

In the present study antioxidative, anti-inflammatory and regenerative effects of hydroalcoholic extract of *Z. jujuba* in 4 doses of 20% and 40% in gel form and enema route and 1500 mg/kg and 3000 mg/kg in oral route in acetic acid induced UC in rat model were investigated. Overall, stimulatory effects on the activities of SOD and GPx, decreasing effects on IL-1 β and MDA level plus MPO activity and healing and regenerative effects in histopathological features were detected in response to use of plant extract. Also, enema route is better than oral administration in all effects and dose-dependent response was detected in both routes of administration.

In previous studies, different plants and derivatives were explored for treatment of UC. It has been reported that hydroalcoholic extract of *Teucrium polium* could increase healthy cells in the colon tissue, decrease the inflammation severity and resolve the inflammation of colon tissue.²⁰ Effects of different doses and routes of administration of hydroalcoholic extract of licorice for 7 day in treatment of UC in rat were investigated. It is found that these treatment decreased the intestinal epithelium damages, TNF- α , IL-6 and NO and increased SOD activity in dose-response pattern.²¹ Improving of pathological conditions of colon, increase of weight and decline in MDA level were seen in rat suffered from UC in response to strawberry extract in dose-response type.²² Similar findings are reported by our group and other scientists for *Berberis vulgaris*,²³ *Melilotus officinalis*,⁹ *Hypericum perforatum*,^{24,25} *Calendula officinalis*²⁶ and *Pistachia atlantica*²⁷ in line with findings of this study. However, the reports about the beneficial effects of using of *Z. jujuba* in inflammatory diseases are scarce. Hydroalcoholic extract of *Z. jujube* can reverse oxidative stress induced by pentylene tetrazole (PTZ) and electroshock in experimental models of epilepsy in rats.²⁸ Also, the beneficial effects hydroalcoholic extract of *Z. jujuba* as alternative treatment in OM as another inflammatory diseases was reported by our group previously.¹⁴

There are several possible mechanisms for these observations. The most important of them is the role of oxidative stress in the pathophysiology of UC. In UC, primary increase of free radicals and secondary hypoxic conditions and chemokines production induced neutrophils and mast cell migration to the colon tissue and increased inflammation and oxidative stress in this organ by help of arachidonic acid metabolites, cytokines and other chemokines.²⁹ *Z. jujuba* contains several polyphenolic compounds such as gallic acid, catechins, caffeic acid, chlorogenic acid, cinnamic acid, coumarin and coumaric acid.³⁰⁻³² These compounds express antiinflammatory and antioxidative effects by blocking the arachidonic acid pathway and inhibiting phospholipase-1, cyclooxygenase and lipooxygenase.³⁰

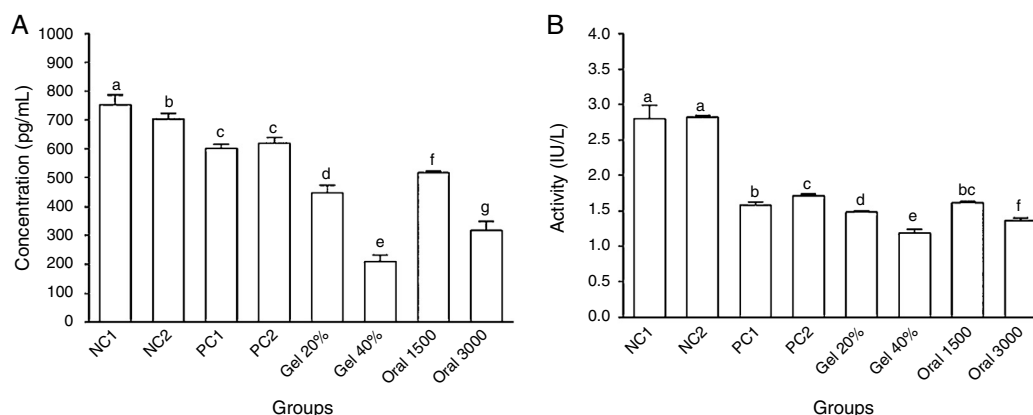


Fig. 3 – Changes of inflammatory indices in colon tissues of rats in different groups. A, IL-1 β level; B, myeloperoxidase activity. Significant statistical differences between groups in each index are indicated by different superscript letter ($p < 0.05$).

Conclusion

Inflammatory diseases such as UC are currently treated with steroidal and non-steroidal anti-inflammatory drugs (NSAIDs), but our findings suggest hydroalcoholic extract of *Z. jujuba* as a new therapeutic agent for UC. This can be concluded from stimulation of healing process and inhibition of the inflammatory and oxidative pathways.

Conflicts of interest

The authors declare no conflicts of interest.

Acknowledgments

Authors wish to thank all staffs of Department of Pharmacology Toxicology, School of Pharmacy, Shiraz University of Medical Sciences, Shiraz, Iran for their cooperation in experimental procedure and analysis. This article was extracted from MSc Thesis of Mr. Ali Ghanbari Saghesloo with supervision of Dr. Nader Tanideh and Dr. Akram Jamshidzadeh. The authors also thanks The Articlepublishers group (www.articlepublishers.ir) for kindly help in article revision.

REFERENCES

- Lutgens MWMD, van Oijen MGH, van der Heijden GJMG, Vleggaar FP, Siersema PD, Oldenburg B. Declining risk of colorectal cancer in inflammatory bowel disease: an updated meta-analysis of population-based cohort studies. *Inflamm Bowel Dis.* 2013;19:789–99.
- Economou M, Zambeli E, Michopoulos S. Incidence and prevalence of Crohn's disease and its etiological influences. *Ann Gastroenterol.* 2009;22:158–67.
- Heydarpour P, Rahimian R, Fakhfour G, Khoshkish S, Fakhraei N, Salehi-Sadaghiani M, et al. Behavioral despair associated with a mouse model of Crohn's disease: role of nitric oxide pathway. *Progr Neuro-Psychopharmacol Biol Psychiatry.* 2016;64:131–41.
- Peterson J, Garges S, Giovanni M, McInnes P, Wang L, Schloss JA, et al. The NIH human microbiome project. *Genome Res.* 2009;19:2317–23.
- Andreoli TE, Fitz JG, Benjamin I, Griggs RC, Wing EJ. *Andreoli and Carpenter's Cecil essentials of medicine.* Elsevier Health Sciences; 2010.
- Seibold F, Brandwein S, Simpson S, Terhorst C, Elson CO. pANCA represents a cross-reactivity to enteric bacterial antigens. *J Clin Immunol.* 1998;18:153–60.
- Cromer WE, Ganta CV, Patel M, Traylor J, Kevil CG, Alexander JS, et al. VEGF-A isoform modulation in a preclinical TNBS model of ulcerative colitis: protective effects of a VEGF164b therapy. *J Transl Med.* 2013;11:207.
- Jiang X, Zhong L, Sun D, Rong L. Magnesium lithospermate B acts against dextran sodiumsulfate-induced ulcerative colitis by inhibiting activation of the NLRP3/ASC/Caspase-1 pathway. *Environ Toxicol Pharmacol.* 2016;41:72–7.
- Safarpour AR, Kaviyani F, Sepehrimanesh M, Ahmadi N, Koochi Hosseinabadi O, Tanideh N, et al. Antioxidant and anti-inflammatory effects of gel and aqueous extract of *Melilotus officinalis* L. in induced ulcerative colitis: a *Rattus norvegicus* model. *Ann Colorect Res.* 2015;3:e29511.
- Kandhare AD, Raygude KS, Ghosh P, Ghule AE, Gosavi TP, Badole SL, et al. Effect of hydroalcoholic extract of *Hibiscus rosa sinensis* Linn. leaves in experimental colitis in rats. *Asian Pac J Trop Biomed.* 2012;2:337–44.
- Baumgart DC, Carding SR. Inflammatory bowel disease: cause and immunobiology. *Lancet.* 2007;369:1627–40.
- Huang Y-L, Yen G-C, Sheu F, Chau C-F. Effects of water-soluble carbohydrate concentrate from Chinese jujube on different intestinal and fecal indices. *J Agric Food Chem.* 2008;56:1734–9.
- Tahergorabi Z, Abedini MR, Mitra M, Fard MH, Beydokhti H. *Ziziphus jujuba*: a red fruit with promising anticancer activities. *Pharmacogn Rev.* 2015;9:99–106.
- Koochi-Hosseinabadi O, Andisheh-Tadmir A, Bahadori P, Sepehrimanesh M, Mardani M, Tanideh N. Comparison of the therapeutic effects of the dietary and topical forms of *Zizyphus jujuba* extract on oral mucositis induced by 5-fluorouracil: a golden hamster model. *J Clin Exp Dentist.* 2015;7:e304–9.
- Mardani M, Afra SM, Tanideh N, Andisheh Tadmir A, Modarresi F, Koochi-Hosseinabadi O, et al. Hydroalcoholic extract of *Carum carvi* L. in oral mucositis: a clinical trial in male golden hamsters. *Oral Dis.* 2016;22:39–45.
- Kazempour N, Nikbin M, Maghsoudlou MT, Sepehrimanesh M. Antioxidant properties of extracts of *Scutellaria lute-caerulea* in vitro. *Online J Vet Res.* 2014;18:75–81.

17. Panahi M, Karimaghai N, Rahmanifar F, Tamadon A, Vahdati A, Mehrabani D, et al. Stereological evaluation of testes in busulfan-induced infertility of hamster. *Comp Clin Pathol*. 2015;24:1051-6.
18. Tamadon A, Nikahval B, Sepehrimanesh M, Mansourian M, Naeini AT, Nazifi S. Epididymis ligation: a minimally invasive technique for preparation of teaser rams. *Vet Surg*. 2010;39:121-7.
19. Yazdani A, Poorbaghi SL, Habibi H, Nazifi S, Rahmani Far F, Sepehrimanesh M. Dietary *Berberis vulgaris* extract enhances intestinal mucosa morphology in the broiler chicken (*Gallus gallus*). *Comp Clin Pathol*. 2013;22:611-5.
20. Mehrabani D, Bahrani F, Hosseini SV, Ashraf MJ, Tanideh N, Rezaianzadeh A, et al. The healing effect of *Teucrium polium* in acetic acid-induced ulcerative colitis in the dog as an animal model. *Middle East J Diges Dis*. 2012;4:40-7.
21. Allizadeh-Naeini M, Tanideh N, Zargari-Samadnejad A, Mehrvarz S. Healing effect of Licorice extract in acetic acid-induced ulcerative colitis in rat. *Res Pharmaceut Sci*. 2012;7:S837.
22. Tanideh N, Akbari Baseri F, Jamshidzadeh A, Ashraf MJ, Kuchi O, Mehrabani D. The healing effect of strawberry extract on acetic acid-induced ulcerative colitis in rat. *World Appl Sci J*. 2014;31:281-8.
23. Tanideh N, Afaridi E, Mehrabani D, Azarpira N, Hosseinzadeh M, Amini M, et al. The healing effect of *Berberis vulgaris* in acetic acid-induced ulcerative colitis in rat. *Middle-East J Scient Res*. 2014;21:1288-94.
24. Dost T, Ozkayran H, Gokalp F, Yenisey C, Birincioglu M. The effect of *Hypericum perforatum* (St. John's Wort) on experimental colitis in rat. *Digest Dis Sci*. 2009;54:1214-21.
25. Tanideh N, Nematollahi SL, Hosseini SV, Hosseinzadeh M, Mehrabani D, Safarpour A, et al. The healing effect of *Hypericum perforatum* extract on acetic acid-induced ulcerative colitis in rat. *Ann Colorect Res*. 2014;2:e25188.
26. Mehrabani D, Ziaei M, Hosseini SV, Ghahramani L, Bananzadeh AM, Ashraf MJ, et al. The effect of *Calendula officinalis* in therapy of acetic acid induced ulcerative colitis in dog as an animal model. *Iran Red Crescent Med J*. 2011;13:884-90.
27. Tanideh N, Masoumi S, Hosseinzadeh M, Safarpour AR, Erjaee H, Koohi-Hosseinabadi O, et al. Healing effect of pistacia atlantica fruit oil extract in acetic acid-induced colitis in rats. *Iran J Med Sci*. 2014;39:522-8.
28. Pahuja M, Mehla J, Reeta KH, Joshi S, Gupta YK. Hydroalcoholic extract of *Zizyphus jujuba* ameliorates seizures, oxidative stress, and cognitive impairment in experimental models of epilepsy in rats. *Epilepsy Behav*. 2011;21:356-63.
29. Pravda J. Radical induction theory of ulcerative colitis. *World J Gastroenterol*. 2005;11:2371-84.
30. Mahajan RT, Chopda MZ. Phyto-pharmacology of *Zizyphus jujuba* mill – a plant review. *Pharmacogn Rev*. 2009;3:320-9.
31. Elaloui M, Laamouri A, Fabre J, Mathieu C, Vilarem G, Hasnaoui B. Distribution of free amino acids, polyphenols and sugars of *Zizyphus jujuba* pulps harvested from plants grown in Tunisia. *Nat Prod Res*. 2015;29:94-7.
32. Liu J, Chen B, Yao S. Simultaneous analysis and identification of main bioactive constituents in extract of *Zizyphus jujuba* var. *sapinosa* (*Zizyphi spinosi* semen) by high-performance liquid chromatography-photodiode array detection-electrospray mass spectrometry. *Talanta*. 2007;71:668-75.