



# Journal of Coloproctology

www.jcol.org.br



## Review Article

# Current management of spontaneous intra-abdominal abscess in Crohn's disease

Ana Teresa Pugas Carvalho<sup>a,\*</sup>, Barbara Cathalá Esberard<sup>a</sup>, Andre da Luz Moreira<sup>b</sup>

<sup>a</sup> Universidade do Estado do Rio de Janeiro (UERJ), Disciplina de Gastroenterologia, Departamento de Medicina Interna, Rio de Janeiro, RJ, Brazil

<sup>b</sup> Universidade do Estado do Rio de Janeiro (UERJ), Disciplina de Coloproctologia, Departamento de Cirurgia Geral, Rio de Janeiro, RJ, Brazil

## ARTICLE INFO

### Article history:

Received 12 May 2016

Accepted 15 May 2016

Available online 4 July 2016

### Keywords:

Crohn's disease

Abdominal abscess

Management

Percutaneous drainage

Surgical treatment

## ABSTRACT

Crohn's disease (CD) is a chronic transmural disease process with approximately 10% of patients developing spontaneous intra-abdominal abscess during the first 5 years after the diagnosis. The symptoms are often nonspecific. The treatment modalities include the use of wide-spectrum antibiotics, imaging-guided percutaneous drainage (PD) and surgical drainage with or without resection. The best initial treatment strategy has not been settled controversial, as there are only retrospective studies with small sample sizes available in the literature. The majority of the patients would eventually need surgery. However a highly selected patient population with small abscess in the absence of fistulas or bowel strictures, especially those naive to immunomodulators or biologics, may respond to medical treatment alone with wide-spectrum antibiotics. The increased use of PD drainage in the last few years has been shown to reduce postoperative morbidities and risk of fecal diversion, allowing for subsequent elective surgery. Varied success rates of PD drainage have been reported in the literature. The initial surgical intervention of CD-related spontaneous abdominal sepsis is mandatory in patients with diffuse peritonitis due to free perforation. Surgery is also indicated in those with failed initial medical treatment and/or PD. This review article was aimed to evaluate the treatment modalities for spontaneous intra-abdominal abscess in CD patients and propose an algorithm for the best management of this complication.

© 2016 Sociedade Brasileira de Coloproctologia. Published by Elsevier Editora Ltda. This is an open access article under the CC BY-NC-ND license (<http://creativecommons.org/licenses/by-nc-nd/4.0/>).

## Tratamento atual de abscesso intra-abdominal espontâneo na doença de Crohn

## RESUMO

A doença de Crohn (DC) é um processo patológico transmural crônico, em que aproximadamente 10% dos pacientes desenvolvem um abscesso intra-abdominal espontâneo durante os primeiros 5 anos após o diagnóstico. Com frequência os sintomas são inespecíficos.

### Palavras-chave:

Doença de Crohn

Abscesso abdominal

\* Corresponding author.

E-mail: [atpugas@yahoo.com.br](mailto:atpugas@yahoo.com.br) (A.T. Carvalho).

<https://doi.org/10.1016/j.jcol.2016.05.003>

2237-9363/© 2016 Sociedade Brasileira de Coloproctologia. Published by Elsevier Editora Ltda. This is an open access article under the CC BY-NC-ND license (<http://creativecommons.org/licenses/by-nc-nd/4.0/>).

Tratamento  
Drenagem percutânea  
Tratamento cirúrgico

As modalidades terapêuticas são o uso de antibióticos de amplo espectro, drenagem percutânea (DP) orientada por imagem, e drenagem cirúrgica com ou sem ressecção. A melhor estratégia terapêutica inicial ainda não ficou estabelecida e há controvérsias, visto que a literatura conta apenas com estudos retrospectivos com pequenas amostras. Em sua maioria, os pacientes acabarão necessitando de cirurgia. Mas uma população altamente selecionada de pacientes, com pequeno abscesso na ausência de fístulas ou constrictões intestinais, especialmente aqueles que jamais foram medicados com imunomoduladores ou agentes biológicos, podem responder exclusivamente ao tratamento clínico com antibióticos de amplo espectro. Foi demonstrado que o uso mais frequente da DP nos últimos anos diminuiu as morbidades pós-operatórias e o risco de desvio fecal, o que possibilita uma subsequente cirurgia eletiva. Na literatura, têm sido relatados percentuais de sucesso variados com a DP. A intervenção cirúrgica inicial para a sepse abdominal espontânea relacionada à DC é obrigatória em pacientes com peritonite difusa, devido à perfuração livre. Também há indicação cirúrgica naqueles pacientes que não conseguiram obter sucesso com o tratamento clínico inicial e/ou DP. Esse artigo de revisão teve por objetivo avaliar as modalidades terapêuticas para o abscesso intra-abdominal espontâneo em pacientes com DC; além disso, propõe um algoritmo para o melhor tratamento dessa complicação.

© 2016 Sociedade Brasileira de Coloproctologia. Publicado por Elsevier Editora Ltda. Este é um artigo Open Access sob uma licença CC BY-NC-ND (<http://creativecommons.org/licenses/by-nc-nd/4.0/>).

### Core tip

Crohn's disease (CD) is a transmural chronic illness with approximately 10% of patients developing spontaneous intra-abdominal abscess within the first 5 years after the diagnosis. CD spontaneous intra-abdominal abscess can be managed with broad-spectrum antibiotics, imaging-guided percutaneous drainage or surgical therapy. The best strategy of treatment is controversial because the current literature is based on retrospective series. This review aims to discuss the role of different treatment options for spontaneous abdominal abscess in CD patients and propose an algorithm for management this complication.

### Introduction

Crohn's disease (CD) is a chronic inflammatory disease process that can affect any parts of the gastrointestinal tract, with the terminal ileum being the most frequent location. Its etiology is likely multifactorial. The Montreal Classification defines the phenotype in three categories: stricturing, penetrating and non-stricturing/non-penetrating.<sup>1</sup> A few retrospective studies have shown a progression from inflammatory to penetrating phenotype within 5 years after the diagnosis of CD, more frequent during the first 2 years. Many CD patients may present with fistulas during the disease course, due to the fact that there is a transmural bowel involvement by CD. Approximately 10% of the patients would develop spontaneous intra-abdominal abscess.<sup>2</sup> Spontaneous septic complications are often detrimental to disease outcome as well as cost to the healthcare system. Nonetheless, almost one third of

patients using immunomodulators and/or biological therapy can develop spontaneous intra-abdominal abscesses.<sup>3,4</sup>

Intra-abdominal abscess is defined as an extra-intestinal infected fluid collection on imaging studies. Spontaneous abscess should not be misinterpreted as abscess from post-operative complications. Therefore, an abscess presenting within 3 months after surgery can be arbitrarily defined as postoperative complications and should not be considered or treated as spontaneous abdominal abscess.

Symptoms of abdominal abscess can be unspecific. The most common symptoms are abdominal pain, fever, diarrhea, and nausea.<sup>3</sup> The presence of acute peritonitis or free perforation from CD is rare. Spontaneous intra-abdominal abscesses are frequently located in the right lower quadrant and they can be exclusively in the abdomen, pelvis or the proximity of psoas muscle. Patients with psoas abscess may present with flank or back pain and limp.

The management of intra-abdominal abscess used to be interventional. The surgical modalities include abscess drainage with or without bowel resection and with or without the construction of a stoma. On the other hand, computerized tomography (CT) or ultrasound (US) imaging-guided percutaneous drainage (PD) has recently gained popularity. The best approach for CD-related intra-abdominal abscess has been in debate. *The European Crohn's and Colitis Organization* (ECCO) recommends that a CD patient with a spontaneous intra-abdominal abscess should be managed with broad-spectrum antibiotics, imaging-guided percutaneous drainage or surgical drainage followed by delayed resection if necessary.<sup>5</sup> If abdominal sepsis is contained, elective surgery should be performed. Conservative medical management should not be considered, if abdominal sepsis persists. However, the published literature has shown conflicting results. Ananthakrishnan et al. analyzed the nationally representative hospitalization sample from more than 1000 American hospitals, including 3296 adult CD-related, non-elective hospitalizations that were complicated by intra-abdominal abscesses. Approximately 39% were

treated by medical treatment alone, 29% with PD, and 32% with surgery, demonstrating an increase in the use of PD since 1998. The presence of complicated CD (stricture or fistulae) was associated with an increased likelihood of surgical intervention; and the admission to a teaching hospital was associated with an increased likelihood of PD, which may be credited to the availability of local expertise. Early intervention, either PD or surgical approach, was associated with a shorter hospitalization stay and lower costs.<sup>6</sup> One of the limitations of the study is that population studied were all inpatients and patients with mild diseases or small abscessed might have been treated as outpatient.

This review was aimed to discuss the role of medical management in CD patients presenting with spontaneous abdominal abscess, to describe the clinical outcomes of imaging-guided PD and to evaluate the surgical indications in those patients.

---

## Medical treatment

The use of wide-spectrum antibiotics targeting gram-negative and anaerobic bacteria is mandatory, once the diagnosis of spontaneous abdominal abscess from CD is confirmed. Ciprofloxacin in combination with metronidazole for 7–21 days is the most common choice. The third-generation cephalosporin plus metronidazole and carbapenems can also be prescribed. Retrospective studies have reported an efficacy of approximately 60% for abscess resolution with parental antibiotics alone. However, over 50% of the patients eventually needed surgery.<sup>7,8</sup> Factors associated with failure in medical therapy included corticosteroid use, the presence of fistula and large abscess size. Small abscess without concurrent fistula had a higher chance of respond to antibiotics alone. This is particularly true in those naive to the use of immunomodulators or biologics.<sup>3,7</sup> The cut-off for size of abscess that could predict treatment response was not clearly identified. However, it is generally believed that abscess greater than 4 cm usually would not respond to medical treatment alone and require drainage.<sup>9</sup> Lee et al. have studied the nonsurgical treatment of CD abscess in 24 patients (19 medical treatment alone and 5 PD) with an overall success of 67%. Cumulative recurrence rate was 12.5% and they all occurred within 7 months from the complete resolution of abscess on follow-up imaging. Significant factors that lead to failure of nonsurgical treatment were the presence of fistula and concurrent use of corticosteroids.<sup>7</sup>

The use of corticosteroids during the management of CD-associated abscess management is controversial. Some authors advocated its use for concomitant severe inflammation in the bowel wall, which can be started after the first dose of intravenous antibiotics.<sup>3,10</sup> In contrast, immunomodulator or biological therapy should not be initiated and should be discontinued in the presence of abdominal abscess. Once abscess resolution is confirmed by imaging studies, we can consider the use of immunomodulator or biological therapy. However, the presence of strictures and abdominal fistulas usually indicates the need of surgical treatment since there might be already an irreversible structural damage in the bowel wall.

Few studies have compared medical, PD and surgical management of CD abscess. Bermejo et al. published a retrospective multi-center study analyzing outcomes of different treatment modalities of abdominal abscess during a 1-year follow-up. Their definition of response was the resolution of the abscess on imaging, and no clinical signs of recurrence within 12 months follow-up. Of the 128 patients included, the authors demonstrated treatment efficacy of 63 percent, 30 percent and 91 percent for medical treatment alone, PD and surgical approach, respectively. Predictors of poor response for the medical treatment alone were the use of immunomodulators, the presence of fistula and large abscess size. No predictors of successful treatment were found in the PD or surgical group.<sup>3</sup> Other studies reported the success of medical treatment in small CD abscess in the absence of other complications and immunomodulators naïve patients.

---

## Imaging-guided PD

The proper use of imaging-guided PD largely relies on the size of abscess. The American College of Radiology recommends imaging-guided PD for CD-related abdominal fluid collections greater than 4 cm.<sup>9</sup> Reported efficacy with PD in CD abdominal abscess ranged from 50% to 92%.<sup>8,11,12</sup> This wide range of success rates may be attributed to a variety of factors, including the timing and techniques of PD and definitions of PD failure.

Various techniques of PD have been described. The *Seldinger* technique is the most common used for PD in CD patients presenting with abdominal abscess. Of note, PD is not always feasible for intra-abdominal abscess, particularly in the presence of intra-mesenteric, interloop or multiloculated abscess. Sometimes the small-caliber catheters may be easily obstructed by necrotic tissue, blood coagulates and thick purulent fluid in the abscess cavity. In these cases, greater caliber catheters could replace the small-sized drainage system. Liu et al. have described a strategy using a sump drain with trocar puncture and continuous irrigation and suction under negative pressure, in order to avoid blockage of the drainage system and allow for faster resolution of abscess.<sup>13</sup>

The PD drainage followed by delayed elective surgery has gained popularity. The rationale is the allowance for time in the improvement of patient's clinical and nutritional conditions, "cool-down" or resolution of abscess or sepsis, and reduction in postoperative morbidities and risk for stoma creation.<sup>14</sup>

In selected patients, PD followed by proper medical treatment may be effective in preventing recurrent abscess, without the need of delayed surgery. Some retrospective studies suggested that PD, when feasible, could deviate the need of urgent surgery and the risk of subsequent septic complications. Nguyen et al. reviewed retrospectively 95 patients presenting with CD spontaneous abscess. Fifty-five patients underwent CT- or ultrasound-guided PD followed by the treatment with biological therapy with or without concomitant immunomodulators and 40 patients underwent initial surgery. The initial surgery group had an increased length of hospital stay when compared with the PD plus biological therapy group (15.5 vs. 5 days), but there were no

differences in abscess recurrence and complications. Abscess recurrence was more frequent within 30 days after treatment and the risk factors for recurrence were perianal disease and ileal active inflammation.<sup>15</sup> This study suggests that the initiation of anti-tumor necrosis factor and/or immunosuppressive therapy when abscesses resolve could protect patients from developing intra-abdominal penetrating disease. In this study, biological therapy was started at the same day of PD in some patients without other septic complications; however, the optimal timing to start the biological therapy is debatable. In authors' opinion, the biological agent can be started within one week after complete resolution of the abscess.

It remains to be controversial and is not well defined whether PD alone can be the first and sole treatment option in CD-related abdominal abscess or it works as an interim procedure allowing subsequent elective surgery. Gutierrez et al. have identified 66 patients with CD abdomino-pelvic abscess treated at the Massachusetts General Hospital (29 with initial surgery vs. 37 with PD). Even though the time to resolution of abdominal or pelvic abscesses in CD was similar between both treatment groups, only one-third of patients treated with PD required surgery within 1 year.<sup>16</sup> Lobatón et al. retrospectively compared 22 CD patients with abdominal abscess who underwent PD alone with 22 controls with immediate surgery. The PD alone patients were only operated when there was PD failure. During a 1-year follow-up, only 27% of PD alone patients were able to achieve durable abscess resolution and the other two thirds have undergone surgical treatment. Abscess size, multilocularity, presence of fistula and use of corticosteroid were not statistically associated with PD failure.<sup>11</sup> In contrast, Garcia et al. have questioned the efficacy of PD alone in a retrospective study, which included 51 CD patients with abdominal abscess during a 10-year period. Recurrent or new abscess were more frequent in the PD approach when compared with the surgical approach (56% versus 12%), with a median follow-up of 3.8 years.<sup>8</sup> The debate will persist until definite answer is obtained by large, randomized controlled trials.

There are some contradictory results in whether PD followed by delayed elective surgery can reduce morbidity as compared with the approach with initial surgery. da Luz Moreira et al. reported no significant increase in postoperative septic complication rate or length of hospital stay by the initial surgery versus the initial PD followed by delayed surgery. However, elective surgery after successful PD achieved a reduced rate of stoma creation when compared with initial surgery. The reported factors associated with the failure of PD were corticosteroid use, colonic phenotype, and multiple or multilocular abscesses, whereas abscess size did not preclude PD success.<sup>12</sup> Xie et al. have shown advantages of PD in a small sample of CD patients. PD was performed using a continuous irrigation and aspiration drainage by a specific device named "three channel aspiration drainage," which contains a two-channel drainage with vacuum aspiration and a fluid inlet tube. The performance of PD was able to reduce postoperative complications and stoma creation, when compared with the initial surgery group, but could not avoid subsequent surgery.<sup>17</sup> On the other hand, Braffors et al. have compared PD-then-delayed surgery with the initial-surgery-alone approach

in 70 patients with CD abdomino-pelvic abscesses at Mount Sinai Medical Center. PD was technically successful in 92% of patients and clinically successful in 74%. They could not find any difference regarding postoperative septic complications and stoma creation but there was an increased length of hospital stay in the PD-then-delayed surgery group.<sup>18</sup> Therefore, it appears that surgery may be avoided in a small selected group of patients with abscess resolution treated with PD alone.

---

## Surgical treatment

The initial surgical treatment of spontaneous abdominal sepsis is the only option for patients with free perforation and diffuses peritonitis. The approach is also indicated in those patients who have failed the initial medical treatment and PD.

Surgical pathological examination of resected bowel specimens has demonstrated the association between penetrating disease and mechanical factors, such as luminal narrowing of the bowel from fibrotic stricture.<sup>19</sup> These findings may explain why the presence of stricture and fistula is frequently associated with the failure of nonsurgical approach and the necessity of surgery with bowel resection.

The surgical approach has been addressed by two recent meta-analyses, which showed results favoring the initial or delayed surgery in CD abdominal abscess. The results demonstrated that surgery appears to be inevitable in the majority of the patients. Nguyen et al. have analyzed nine studies including 603 patients. The overall rate of abscess resolution was 57% in the medical group as compared with 81% in the surgical group, suggesting that initial surgical management could be superior to medical management.<sup>20</sup> He et al. have looked at other nine studies including 513 patients and could not find significance difference in postoperative recurrent abscess between the preoperative PD and initial surgery groups.<sup>21</sup> Therefore, it is not clear whether the PD-then-elective surgery approach is better than the initial surgery approach.

It is generally believed that urgent or semi-urgent surgery for CD-associated abscess should be avoided, if possible. Some authors proposed that a delayed surgery, within 6 to 8 weeks after antibiotic treatment and PD would not only permit the optimization of clinical and nutritional status but also provide the window for preoperative endoscopic and imaging work-up to delineate the anatomy and avoid unexpected intraoperative findings. A study of 94 patients from the Cleveland Clinic have shown that the PD-then-delayed surgery gave higher quality-adjusted life-years, was more cost-effective, and had lower risk for stoma creation.<sup>12</sup> The presence of enterocutaneous fistula after PD was not considered a failure since all patients were submitted to elective resection after sepsis control. Poritz et al. have proposed a treatment algorithm to treat CD-associated spontaneous abdominal abscess beginning with an initial percutaneous drainage of the abscess, 5–7 days of IV antibiotics with simultaneous high-dose corticosteroids and hyperalimentation, followed by planned one-stage resection with primary anastomosis. Nineteen consecutive patients were treated with this protocol with acceptable morbidity and low rates of stoma creation.<sup>22</sup>

In patients undertaking the initial surgery approach, the stoma creation after bowel resection is usually required in the presence of abdominal sepsis, with few exceptions. Many patients with spontaneous CD abscess are nutritionally depleted and are using various immunosuppressant medications, such as high-dose corticosteroids, azathioprine or anti-TNF agents. Yamamoto et al. reported that a low pre-operative albumin level, corticosteroid use, and abscess or any fistula at the time of surgery were associated with post-operative septic complications. The risk for sepsis was as high as 50% when all factors were present.<sup>23</sup> Stoma creation was aimed to reduce postoperative complications, despite a dearth of evidence on this topic. The indications for loop covering stoma or split stomas are at the surgeon's discretion for this high-risk group of patients. Some surgeons believed that loop stomas might not completely avoid anastomotic leak but could minimize adverse consequences of this complication and facilitate staged stoma closure. Merge et al. reviewed 80 CD patients that underwent stoma creation, including 63 split stomas and 17 covering loop ileostomies and found that temporary fecal diversion was beneficial in high-risk patients after ileocolonic resection despite a 19% rate of postoperative complications.<sup>24</sup>

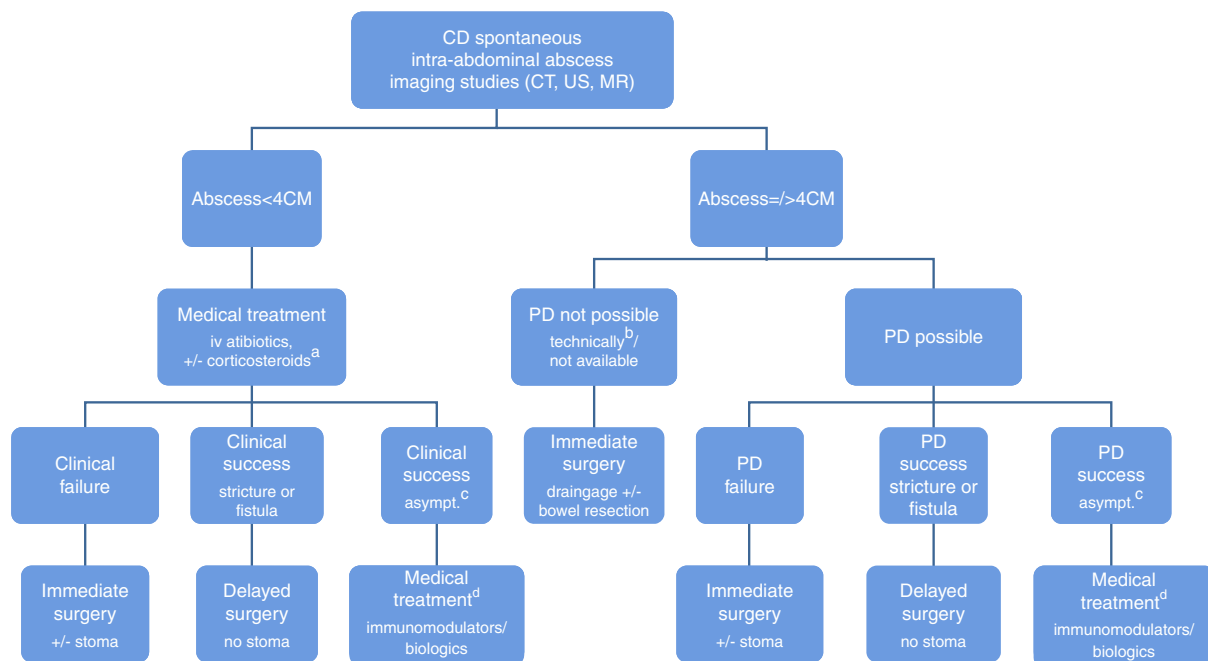
Finally, there is a lack of data on laparoscopic surgery for CD patients with penetrating disease. In selective cases, it is feasible to performed drainage and resection by minimally invasive techniques. Whether initial or delayed surgery can be performed safely by laparoscopic approach it is still to be determined.

## Conclusions

Current data shows that for adult CD patients with spontaneous abdominal abscess:

- Small abscesses can be treated with antibiotics alone;
- Large abscesses should be drained with image-guided PD if feasible;
- In a highly selected group of patients without obstructing symptoms or abdominal fistulas, medical treatment or PD alone could be successful in preventing recurrent abscess;
- The majority of patients will eventually need surgery;
- Initial surgical drainage is effective in most cases however it can increase postoperative morbidity;
- PD followed by delayed elective surgery appears to decrease morbidity and avoid stoma creation;

It is important to emphasize that current literature is based in retrospective studies with bias, issue of sample sizes, and some contradictory results. The definition of treatment success is also heterogeneous and some studies suffer from a short follow-up. Prospective and larger studies are necessary to better understand the impact of CD spontaneous sepsis in the healthcare system and to choose the best treatment options in different clinical scenarios. A suggested algorithm for CD spontaneous abscess management is presented in Fig. 1.



**Fig. 1 – Algorithm proposed for the management of CD spontaneous abdominal abscess.**

CD, Crohn's disease; PD, percutaneous drainage.

<sup>a</sup> Corticosteroids may be considered in the presence of severe active inflammation in the bowel wall.

<sup>b</sup> Interloop, intra-mesenteric or multiloculated abscess.

<sup>c</sup> Asymptomatic patients after complete abscess resolution on imaging studies (CT, US, MR).

<sup>d</sup> Less chance of definitive medical treatment success in non-naïve immunomodulator/biological patients; consider delayed surgery.



---

## Conflicts of interest

The authors declare no conflicts of interest.

## REFERENCES

---

- Satsangi J, Silverberg MS, Vermeire S, Colombel JF. The Montreal classification of inflammatory bowel disease: controversies, consensus, and implications. *Gut*. 2006;749–53.
- Yamaguchi A, Matsui T, Sakurai T, Ueki T, Nakabayashi S, Yao T, et al. The clinical characteristics and outcome of intraabdominal abscess in Crohn's disease. *J Gastroenterol*. 2004;441–8.
- Bermejo F, Garrido E, Chaparro M, Gordillo J, Manosa M, Algaba A, et al. Efficacy of different therapeutic options for spontaneous abdominal abscesses in Crohn's disease: are antibiotics enough? *Inflamm Bowel Dis*. 2012;1509–14.
- Cosnes J, Cattani S, Blain A, Beauverie L, Carbonnel F, Parc R, et al. Long-term evolution of disease behavior of Crohn's disease. *Inflamm Bowel Dis*. 2002;244–50.
- Dignass A, Van Assche G, Lindsay JO, Lemann M, Soderholm J, Colombel JF, et al. The second European evidence-based consensus on the diagnosis and management of Crohn's disease: current management. *J Crohns Colitis*. 2010;28–62.
- Ananthakrishnan AN, McGinley EL. Treatment of intra-abdominal abscesses in Crohn's disease: a nationwide analysis of patterns and outcomes of care. *Dig Dis Sci*. 2013;2013–8.
- Lee H, Kim YH, Kim JH, Chang DK, Son HJ, Rhee PL, et al. Nonsurgical treatment of abdominal or pelvic abscess in consecutive patients with Crohn's disease. *Dig Liver Dis*. 2006;659–64.
- Garcia JC, Persky SE, Bonis PA, Topazian M. Abscesses in Crohn's disease: outcome of medical versus surgical treatment. *J Clin Gastroenterol*. 2001;409–12.
- Lorenz JM, Funaki BS, Ray CE Jr, Brown DB, Gemery JM, Greene FL, et al. ACR appropriateness criteria on percutaneous catheter drainage of infected fluid collections. *J Am Coll Radiol*. 2009;837–43.
- Felder JB, Adler DJ, Korelitz BI. The safety of corticosteroid therapy in Crohn's disease with an abdominal mass. *Am J Gastroenterol*. 1991;1450–5.
- Lobaton T, Guardiola J, Rodriguez-Moranta F, Millan-Scheidig M, Penalva M, De Oca J, et al. Comparison of the long-term outcome of two therapeutic strategies for the management of abdominal abscess complicating Crohn's disease: percutaneous drainage or immediate surgical treatment. *Colorectal Dis*. 2013;1267–72.
- da Luz Moreira A, Stocchi L, Tan E, Tekkis PP, Fazio VW. Outcomes of Crohn's disease presenting with abdominopelvic abscess. *Dis Colon Rectum*. 2009;906–12.
- Liu S, Ren J, Gu G, Wang G, Han G, Yan D, et al. Comparative outcomes of trocar puncture with sump drain, percutaneous drainage, and surgical drainage in the management of intra-abdominal abscesses in Crohn's disease. *Surg Innov*. 2014;580–9.
- Zerbib P, Koriche D, Truant S, Bouras AF, Vernier-Massouille G, Seguy D, et al. Pre-operative management is associated with low rate of post-operative morbidity in penetrating Crohn's disease. *Aliment Pharmacol Ther*. 2010;459–65.
- Nguyen DL, Sandborn WJ, Loftus EV Jr, Larson DW, Fletcher JG, Becker B, et al. Similar outcomes of surgical and medical treatment of intra-abdominal abscesses in patients with Crohn's disease. *Clin Gastroenterol Hepatol*. 2012;400–4.
- Gutierrez A, Lee H, Sands BE. Outcome of surgical versus percutaneous drainage of abdominal and pelvic abscesses in Crohn's disease. *Am J Gastroenterol*. 2006;2283–9.
- Xie Y, Zhu W, Li N, Li J. The outcome of initial percutaneous drainage versus surgical drainage for intra-abdominal abscesses in Crohn's disease. *Int J Colorectal Dis*. 2012;199–206.
- Bafford AC, Coakley B, Powers S, Greenwald D, Ha CY, Weintraub J, et al. The clinical impact of preoperative percutaneous drainage of abdominopelvic abscesses in patients with Crohn's disease. *Int J Colorectal Dis*. 2012; 953–8.
- Oberhuber G, Stangl PC, Vogelsang H, Schober E, Herbst F, Gasche C. Significant association of strictures and internal fistula formation in Crohn's disease. *Virchows Arch*. 2000;293–7.
- Nguyen DL, Nguyen ET, Bechtold ML. Outcomes of initial medical compared with surgical strategies in the management of intra-abdominal abscesses in patients with Crohn's disease: a meta-analysis. *Eur J Gastroenterol Hepatol*. 2015;235–41.
- He X, Lin X, Lian L, Huang J, Yao Q, Chen Z, et al. Preoperative percutaneous drainage of spontaneous intra-abdominal abscess in patients with Crohn's disease: a meta-analysis. *J Clin Gastroenterol*. 2014.
- Poritz LS, Koltun WA. Percutaneous drainage and ileocelectomy for spontaneous intraabdominal abscess in Crohn's disease. *J Gastrointest Surg*. 2007;204–8.
- Yamamoto T, Allan RN, Keighley MR. Risk factors for intra-abdominal sepsis after surgery in Crohn's disease. *Dis Colon Rectum*. 2000;1141–5.
- Mege D, Bege T, Beyer-Berjot L, Loundou A, Grimaud JC, Brunet C, et al. Does faecal diversion prevent morbidity after ileocecal resection for Crohn's disease? Retrospective series of 80 cases. *ANZ J Surg*. 2015.