



Journal of Coloproctology

www.jcol.org.br



Original Article

A randomized trial study on the effect of amniotic membrane graft on wound healing process after anal fistulotomy



Ghahramani Leila^a, Pirayeh Saeideh^a, Khazraei Hajar^a, Bagher pour Ali^a,
Hosseini Seyed Vahid^a, Noorafshan Ali^b, Safarpour Ali Reza^{c,*}, Mousavi Laleh^a

^a Shiraz University of Medical Sciences, Colorectal Research Center, Shiraz, Iran

^b Shiraz University of Medical Sciences, Anatomy Department, Stereology Research Center, Shiraz, Iran

^c Shiraz University of Medical Sciences, Gastroenterohepatology Research Center, Shiraz, Iran

ARTICLE INFO

Article history:

Received 19 December 2016

Accepted 27 March 2017

Available online 15 May 2017

Keywords:

Anal fistula

Human amniotic membrane

Wound healing

Post-operative complication

ABSTRACT

Objective: Human amniotic membrane (HAM) used as a wound coverage for more than a century. The aim of this study is to evaluate the efficacy of amniotic membrane on wound healing and reduce post-operative complication.

Study design: Randomized clinical trial study.

Place and duration of study: Surgery Department, Shahid Faghihi Hospital, Shiraz, in the period of between Sep. 2014 and Nov. 2015.

Methodology: 73 patients with anal fistula were divided into two groups. The patients suffered from simple perianal fistula (low type) without any past medical history. Fistulotomy were performed for all of them and in interventional group HAM were applied as biologic dressing. Their wound healing improvement was evaluated post-operative in two groups.

Results: From 73 patients participated in the study, 36 patients were in control group and 37 patients were in intervention group. According to the analysis of images taken from the wound, the rate of wound healing was 67.39% in intervention group and 54.51% in control group ($p < 0.001$). Discharge, pain, itching and stool incontinency was lower in intervention group. Analysis of pathology samples taken from the wound showed no differences between two groups.

Conclusion: HAM application could lead to improvement of wound healing and reduced post-operative complications. In conclusion, HAM may act as a biologic dressing in the patients with anal fistula.

© 2017 Sociedade Brasileira de Coloproctologia. Published by Elsevier Editora Ltda. This is an open access article under the CC BY-NC-ND license (<http://creativecommons.org/licenses/by-nc-nd/4.0/>).

* Corresponding author.

E-mail: colorectal2@sums.ac.ir (S.A. Reza).

<http://dx.doi.org/10.1016/j.jcol.2017.03.006>

2237-9363/© 2017 Sociedade Brasileira de Coloproctologia. Published by Elsevier Editora Ltda. This is an open access article under the CC BY-NC-ND license (<http://creativecommons.org/licenses/by-nc-nd/4.0/>).

Ensaio clínico randomizado sobre o efeito do enxerto de membrana amniótica sobre o processo de cicatrização após fistulotomia anal

R E S U M O

Palavras-chave:

Fístula anal
Membrana amniótica humana
Cicatrização da ferida
Complicação pós-operatória

Objetivo: Membrana amniótica humana (MAH) tem sido usada para cobrir feridas por mais de um século. O objetivo deste estudo é avaliar a eficácia da membrana amniótica na cicatrização de feridas e reduzir complicações pós-operatórias.

Desenho do estudo: Ensaio clínico randomizado.

Local e duração do estudo: Departamento de Cirurgia, Shahid Faghihi Hospital, Shiraz, Irã, entre setembro de 2014 a novembro de 2015.

Método: 73 pacientes com fístula anal foram divididos em dois grupos. Os pacientes sofriam de fístula perianal simples (tipo baixo) sem histórico médico prévio. A fistulotomia foi realizada em todos eles e no grupo intervenção, MAH foi aplicada como curativo biológico. A melhora da cicatrização foi avaliada no período pós-operatório em dois grupos.

Resultados: De 73 pacientes que participaram do estudo, 36 pacientes eram do grupo controle e 37 pacientes do grupo intervenção. De acordo com a análise das imagens da ferida, a taxa de cicatrização foi 67,39% no grupo intervenção e 54,51% no grupo controle ($p < 0,001$). Secreção, dor, prurido e incontinência fecal foi menor no grupo intervenção. A análise das amostras patológicas retiradas da ferida não mostrou diferenças entre os dois grupos.

Conclusão: A aplicação de MAH pode levar à melhoria da cicatrização de feridas e reduzir as complicações pós-operatórias. Em conclusão, a MAH pode atuar como um curativo biológico nos pacientes com fístula anal.

© 2017 Sociedade Brasileira de Coloproctologia. Publicado por Elsevier Editora Ltda. Este é um artigo Open Access sob uma licença CC BY-NC-ND (<http://creativecommons.org/licenses/by-nc-nd/4.0/>).

Introduction

Fistula-in-ano disease usually exists after anorectal infection. There are many treatment options for management of anal fistulas with minimum chance of incontinence and recurrence. Surgical managements have to eliminate the septic foci and any associated epithelized tract to avoid recurrence and preserve the anal sphincter function.

All of the options have different success rates. Fistulotomy used in the underlying sphincter tissue and is recommended for low fistulas with reported success rates varying from 29% to 53%. Success rates with plug have been comparable or inferior to the advancement flap (48–62%). The flap should consist of the part of the internal sphincter and mucosa with a broad base of blood supply and should be sutured without tension. The success rate can be raised by removing the underlying infected anal gland and curetting the rest of the tract.¹

Setonisa less invasive approach with minimal damage to the sphincter. However the discomfort caused to the patient during the long time required for wound healing is the main disadvantage of this approach. However, a cutting seton can have better (up to 99%) success rate, it can cause severe discomfort to the patient and also, can have 18–25% incidence of incontinence. Draining seton can have 20–40% persistent fistula rate, but with a low incidence of incontinence.²

In 2006, ligation of inter sphincteric fistula tract (L.I.F.T.) introduced by Rojanasakul for the first time as a total sphincter saving procedure.³ Healing rate after 6–7 weeks is usually ranging from 68% to 83%. Video assisted anal fistula treatment (VAAFT) described by Prof. Meineró, that is done with

the rigid endoscope and the tract is cauterized, curetted and the internal opening is stapled.⁴

Cochrane database have described that no major difference was seen between the various techniques used if recurrence rates are concerned.⁵ Thus there is no single method that is perfect and physician has to choose the surgery depending on his/her experience, the type of fistula and the other local conditions.

Many post-operative complications are because of dysfunction of wound healing. Vascularity of anal canal is important but the main reason is infection and lack of scare recovery due to scare situation and humid dressing. So, complications like pain, itching, discharge and recurrence occurred.

Human amniotic membrane (HAM) is the inner layer of the fetal membranes and has bio-compatibility, easy availability, elasticity and stability and it has been used as an alternative biomaterial for research in many surgeries and wound-healing procedures. Amniotic membrane has been used in different organs for example, many surgeons evaluated the efficacy of HAM as a biologic dressing in burn wounds or in corneal epithelium reconstruction with transplantation of epithelial cells on a lyophilized amniotic membrane (LAM) or in gastrointestinal tract surgeries.^{6,7} Many studies assessed the efficacy of HAM as a biologic dressing in skin ulcers reported better outcomes in comparison to some other methods. Moreover, in a few studies, HAM has been evaluated in GI tract of animal models and the results showed accelerating wound healing process.⁸ Uludag et al. used HAM patch in colon anastomosis in rats and reported that using HAM decreases dehiscence rate, intra-abdominal abscesses, anastomotic leakage, adhesion formation and intestinal obstruction.⁹

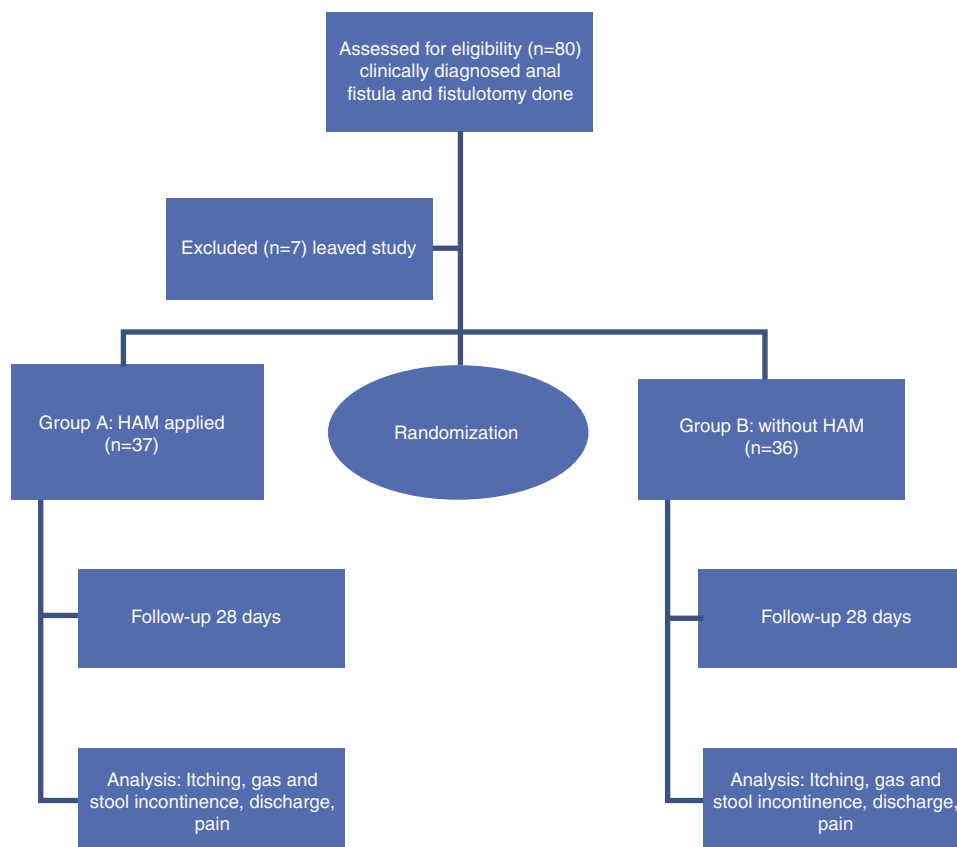


Fig. 1 – Flow diagram RCT.

However, HAM has been put into practice for less than a decade and more studies are needed for better evaluation and the probable long-term adverse effects of HAM should be evaluated in further studies. The aim of this study was to evaluate the HAM effect on wound healing acceleration in the post fistulotomy procedure.

Methodology

The study has been designed as a randomized clinical trial to evaluate efficacy of HAM in healing of fistula in-Ano. 73 patients with clinical diagnosis of fistula in-Ano were evaluated in Shahid Faghihi Hospital of Shiraz University of Medical Sciences between September 2014 and November 2015. All patients suffered low type fistula in-Ano that was confirmed by colorectal surgeon with physical examination and anoscopy. The patient were randomly allocated into two groups; fistulotomy with marsupialization and HAM applying on wound in group A and fistulotomy with marsupialization in group B as control group (standard procedure for low type fistula).

The inclusion criteria were as follows: clinical diagnosis of low type fistula (sphincter involvement <30%), age 18–65 years, and American society of anesthesiologists class I or II. The exclusion criteria included the following; 1) immune compromised patients such as T.B, AIDS or DM received steroid drugs >20 mg/day; 2) inflammatory bowel disease; 3) past medical

history of previous anal surgeries; 4) history of gas or stool incontinence; 5) allergy to egg; 6) refuse to participation in this study; 7) BMI > 30; 8) fistula with abscess; 9) high type fistula (sphincter involvement >30%); 10) previous pelvic radiation; 11) perianal dermatitis.

Written informed consent form was filled by all the patients that participated in the study before surgery. Randomization was done by block randomization permuted total patients was 80 that 73 participants allocated in each group (we lost 7 patients in follow-up). The patients in the two groups received prophylactic dose of metronidazole just before anesthesia and two doses post-operatively at 8 and 16h. All patients operated in prone position, after anoscopy and identification of fistula tract and internal, external orifice of fistula. Fistulotomy was done in eligible participants. Performing fistulotomy and curettage in group A, then HAM applied on the wound of fistula. HAM was fixed on the side of wound by monocryl 4/0 in four points the same as marsupialization. Then, digital photography was taken from 10 cm distance. Finally surgical dressing was applied. In group B, after fistulotomy and curettage, marsupialization was done in four points of the side wall with monocryl 4/0 and dressing the same as group A. Digital photography was taken also from 10 cm distance as well. Normal diet was start after 1 day and dressing was removed. Then, the patients discharge in second days, if they did not have any complications such as unpredictable pain, abnormal discharge and cellulites. Both groups were operated by colorectal surgeon. Another colorectal surgeon

Table 1 – Demographic data from patients under simple surgery and HAM with surgery (percent).

Group	Male	Female	Mean age ± SD
Simple surgery	31 (86.1%)	5 (13.9%)	39.94 ± 10.77
Surgery with HAM	20 (54.1%)	17 (45.9%)	37.32 ± 10.27

Table 2 – Discharge, itching, pain, incontinence parameters.

Parameter	p-value	Odds ratio	95% confidence interval	
			Lower	Upper
Discharge	0.000	2.29	1.53	3.42
Itching	0.000	4.82	2.65	8.78
Pain	<0.0001	1.61	1.34	1.93
Fecal incontinence	0.007	–	–0.72	–0.11

visited the patients 3, 7, 14, 21 and 28th days post operation that he was blinded to allocation of the two groups. Follow-up data form was complete with attention to sign and symptom of the patients (Fig. 1). Itching, gas and stool incontinence, discharge, pain scoring was determined by using VAS system. In second visit (2 weeks post operation), digital photograph was taken again in the same distance. Tissue biopsy was taken of 10 patients in both groups randomly. Therefore, primary outcome in this study was wound healing acceleration by HAM that was evaluated subjectively and objectively. Secondary outcome was infection and abscess formation. Question forms evaluated wound healing and infection subjectively and digital photograph (digital image: stereolith), tissue biopsy taken helped us for objective evaluation (10 participants in each group).

This study was approved by the ethics committee of Shiraz University of Medical Sciences and was registered with the Iranian Clinical Trial Register (IRCT: 201310219936N6).

Statistics

Statistical analysis was performed by SPSS software (version 16) and also SAS (for categorical repeated measurement). In descriptive analysis quantitative variables were revealed by mean ± SD, and qualitative variables were showed by frequency and percent. Qualitative variables were pain, discharge and itching. Quantitative variable was percent of scar recovery.

They were measured during times after surgery. Repeated measurement analysis (RMA) was done for evaluation of significant changes in the outcome variables. Qualitative RMA and quantitative RMA were performed by SPSS and SAS soft wares respectively. Generalized estimating equation (GEE) was the method for discharge assay. Two samples t-test, χ^2 test and fisher exacted test also were uses in appropriate comparisons. p-value greater than 0.05 was considered significant.

Results

80 patients evaluated and 7 of patients leave the study, 36 of them had simple fistulotomy (5 female and 31 male) and 37 of patients had fistulotomy with HAM graft (17 female and 20 male). In this study, mean age of patients with simple fistulotomy was 39.9 years and mean age of patients with HAM was 37.3 years with no significant difference (Table 1).

In this study, variables like sex, age, history of fissure before surgery, time and type of surgery and their effects on discharge assayed (Table 2). Time and discharge had significant difference ($p = 0.003$), that means increase of time decrease chance of discharge (OR = 0.96). Also, surgery with HAM in comparison with simple fistulotomy decrease chance of discharge more than two times (OR = 2.29). Sex, age and fissure did not have significant difference and showed that two groups were equal as sex and age.

Itching and fissure before surgery, type of surgery and time had significant difference. GEE results in itching showed significant difference in time ($p = 0.004$) and by increase of time, chance of lack of itching increased (OR = 1.04). There was significant difference between two groups for itching ($p < 0.05$) and chance of lack of itching in group 1 was more than 4 times of group zero (OR = 4.82). Fissure in clinical exam before surgery affects itching significantly ($p < 0.05$). Chance of lack of itching in patients with fissure was lower than patients without fissure (OR = 0.17). Sex and age did not show any difference on itching ($p = 0.421$, $p = 0.07$), respectively.

For Analysis the data for Pain SAS software used and GEE marginal modeling method showed that time significantly affected ($p < 0.05$) and by spending more time chance of lack of pain increased (OR = 2.14). Two groups demonstrated significant difference in pain ($p < 0.05$) and chance of lack of pain in group zero was less than group 1 (OR = 0.47). So, surgery with HAM suggested as better surgery in comparison to another surgery. Sex and age did not show any difference on pain.

Percent of healing

According to the photographic data in day of surgery and 14 days after that, percent of scare recovery obtained by digital image analysis. Mean ± SD of percent of recovery in group without HAM was 54.51 ± 4.86 and in group that used HAM graft was 67.39 ± 4.69. The difference between two groups was significant ($p < 0.0001$) that means use of HAM increased rate of scare recovery.

Fecal incontinence parameter

Lack of fecal incontinency in interventional group was significantly less than control group (p -value = 0.007). Wexner score was used for incontinency evaluation.

Pathology

Mann–Whitney test used for comparison between two groups and there was no significant difference between them as pathologic data (p -value = 0.76).

Discussion

Usually 70.7% of fistulas were healed in at least 1 year of follow-up. Fistula-in-ano is a challenging condition to manage despite the technological advances and it is not a gold standard treatment algorithm for it. Low transsphincteric fistulas are treated by fistulotomy successfully while complex fistulas are managed by advancement flap repair, cutting seton, partial fistulotomy, stem cell injection, fibrin or dermal collagen glue injection, plug, VAAFT, LIFT, and FiLaC, but evidence on healing, recurrence, and safety of these options is not clarified completely. A study on anal fistula is needed to define kind of fistula (low, high, transsphincteric, intersphincteric) and outcome measures (healing time, incontinence).

Human amniotic membrane (HAM) has bio-compatibility, easy availability, elasticity and stability that researchers have encouraged to consider it as a biologic dressing and appropriate bio-prosthesis for more than 100 years. Many surgeons examined the efficacy of HAM as a biologic dressing in their treatment methods such as burn wounds treatment or in gastrointestinal tract surgeries and desirable outcomes were reported.⁶ Amnion cells synthesize peptides of the innate immunity system, like as beta-defensins, elastase-inhibitors, elafin, lactoferrin, or IL-1-RA. HAM had antimicrobial effect due to these immune factors. Also, HAM synthesizes numerous growth factors such as epithelial growth factor (EGF), human growth factor (HGF), keratinocyte growth factor (KGF), basic fibroblast growth factor (bFGF), and tissue growth factors (TGF- α , TGF- β -1, TGF- β -2, and TGF- β -3) and expected to accelerate reepithelialization and wound-healing by the activation of keratinocytes.¹⁰ Collagen type IV and laminin are mainly compositions of basement membrane and is pivotal for coherence between dermal layers and the epithelial.

Our findings showed that repairing anal fistula with HAM results in better outcome compared to simple repair. This is in concordance with the results of other studies which reported the application of HAM in repairing recto-vaginal fistulas.⁶

We standardized histologic findings by using a modified scoring system and provide a quantitative comparative context. Although quantitative assessment of anal fistula healing process is challenging, we believe it would help researchers for more accurate comparison.

Many surgical approaches for decrease healing time used such as: Fistulotomy with 8.3% minor incontinence and 8.3% recurrence rate,¹¹ Advancement flap with 29% incontinence and 10% recurrence,¹² York Mason approach,¹³ Seton, Plug, fibrin glue¹⁴ or Stem cell injection with complex (high or transsphincteric) anal fistulae.

According to our knowledge, this study is first study to evaluate the effect of HAM on wound healing post fistulotomy. The main positive point seems comparison of HAM effect by quantitative and qualitative measurement.

Conclusion

Though the anal fistula is troublesome to the surgeons, it seems be improved by using the HAM graft. Our results seem to demonstrate that this technique is both simple and effective and would result in better surgical and histological outcomes comparing to simple repair. HAM increased rate of recovery and it suggested that HAM could be used for further research on patients' treatment.

Conflicts of interest

The authors declare no conflicts of interest.

Acknowledgements

This article was extracted from the thesis of Dr. Pirayeh, no. 5180, and approved by the research vice-chancellor of Shiraz University of Medical Sciences. Hereby, the authors would like to thank this vice-chancellery for financially supporting the study.

REFERENCES

- Mushaya C, Bartlett L, Schulze B, Ho YH. Ligation of intersphincteric fistula tract compared with advancement flap for. *Am J Surg*. 2012;204:283–9.
- Galis-Rozen E, Tulchinsky H, Rosen A, Eldar S, Rabau M, Stepanski A, et al. Long-term outcome of loose seton for complex anal fistula: a two-centre study of patients with and without Crohn's disease. *Colorectal Dis*. 2010;12:358–62.
- Rojanasakul A. LIFT procedure: a simplified technique for fistula-in-ano. *Tech Coloproctol*. 2009;13:237–40.
- Meinero P, Mori L. Video-assisted anal fistula treatment (VAAFT): a novel sphincter-saving procedure for treating complex anal fistulas. *Tech Coloproctol*. 2011;15:417–22.
- Jacob TJ, Perakath B, Keighley MR. Surgical intervention for anorectal fistula. *Cochrane Database Syst Rev*. 2010;12. CD006319.
- Roshanravan R, Ghahramani L, Hosseinzadeh M, Mohammadipour M, Moslemi S, Rezaianzadeh A, et al. A new method to repair recto-vaginal fistula: Use of human amniotic membrane in an animal model. *Adv Biomed Res*. 2014;3:114.
- Ahn JI, Lee DH, Ryu YH, Jang IK, Yoon MY, Shin YH, et al. Reconstruction of rabbit corneal epithelium on lyophilized amniotic membrane using the tilting dynamic culture method. *Artificial Organs*. 2007;31:711–21.
- Ghahramani L, Jahromi AB, Dehghani MR, Ashraf MJ, Rahimikazerooni S, Rezaianzadeh A, et al. Evaluation of repair in duodenal perforation with human amniotic membrane: an animal model (dog). *Adv Biomed Res*. 2014;17:113.
- Uludag M, Citgez B, Ozkaya O, Yetkin G, Ozcan O, Polat N, et al. Effects of amniotic membrane on the healing of primary colonic anastomoses in the cecal ligation and puncture model of secondary peritonitis in rats. *Int J Colorectal Dis*. 2009;24:559–67.
- Loeffelbein DJ, Rohleder NH, Eddicks M, Baumann CM, Stoeckelhuber M, Wolff KD, et al. Evaluation of human amniotic membrane as a wound dressing for split-thickness skin-graft donor sites. *BioMed Res Int*. 2014;572183.
- Pescatori M, Ayabaca SM, Cafaro D, Iannello A, Magrini S. Marsupialization of fistulotomy and fistulectomywounds

- improves healing and decreases bleeding: a randomized controlled trial. *Colorectal Dis.* 2006;8:11-4.
12. Perez F, Arroyo A, Serrano P, Candela F, Perez MT, Calpena R. Prospective clinical and manometric study of fistulotomy with primary sphincter reconstruction in the management of recurrent complex fistula-in-ano. *Int J Colorectal Dis.* 2006;21:522-6.
 13. Cadeddu F, Salis F, Lisi G, Ciangola I, Milito G. Complex anal fistula remains a challenge for colorectal surgeon. *Int J Colorectal Dis.* 2015;30:595-603.
 14. Malik AI, Nelson RL. Surgical management of anal fistulae: a systematic review. *Colorectal Dis.* 2008;10:420-30.