



Journal of Coloproctology

www.jcol.org.br



Case Report

Acute appendicitis mimicking acute scrotum: a rare complication of a common abdominal inflammatory disease



Kelly Cristine de Lacerda Rodrigues Buzatti^{a,*}, Marcus Vinícius Capanema Gonçalves^a, Rodrigo Gomes da Silva^{a,b}, Beatriz Deoti e Silva Rodrigues^{a,b}

^a Universidade Federal de Minas Gerais (UFMG), Hospital das Clínicas, Belo Horizonte, MG, Brazil

^b Universidade Federal de Minas Gerais (UFMG), Faculdade de Medicina, Belo Horizonte, MG, Brazil

ARTICLE INFO

Article history:

Received 2 June 2017

Accepted 9 August 2017

Available online 12 October 2017

Keywords:

Acute appendicitis

Appendectomy

Acute abdomen

Spermatic cord torsion

Acute scrotum

ABSTRACT

Introduction: Acute appendicitis is the most common surgical disease of the abdomen in clinical practice, affecting mainly young adults. It has a wide variety of clinical presentations, due to the anatomical variation of the cecal appendix. Its presentation as acute scrotum and scrotal abscess is quite rare and atypical, occurring mainly in young male patients with patent processus vaginalis.

Case presentation: An 18-years-old male patient attended the emergency unit complaining of diffuse abdominal pain, fever and hyporexia for four days followed by inflammatory signs in the scrotum. He was taken to the operation room after diagnosis of scrotal and abdominal sepsis. During scrotum exploration, pus was found inside the right hemiscrotum coming down from the groin and communicating with the abdominal cavity. The laparotomy found perforated appendicitis and peritonitis leading to the scrotal abscess. The abscess was drained, appendectomy was performed and the scrotal and abdominal cavity were washed with saline solution. Despite postoperative complications such as pneumonia and intra-abdominal abscess, the reported patient recovered and was discharged in the 44th postoperative day.

Conclusion: Acute appendicitis can mimic acute scrotum and surgeons must have a high index of suspicion of this complication for diagnosing. This unusual clinical presentation may be challenging and can delay the diagnosis leading to perforated peritonitis.

© 2017 Sociedade Brasileira de Coloproctologia. Published by Elsevier Editora Ltda. This is an open access article under the CC BY-NC-ND license (<http://creativecommons.org/licenses/by-nc-nd/4.0/>).

* Corresponding author.

E-mail: kellybuzatti@gmail.com (K.C. Buzatti).

<https://doi.org/10.1016/j.jcol.2017.08.004>

2237-9363/© 2017 Sociedade Brasileira de Coloproctologia. Published by Elsevier Editora Ltda. This is an open access article under the CC BY-NC-ND license (<http://creativecommons.org/licenses/by-nc-nd/4.0/>).

Apendicite aguda mimetizando escroto agudo: uma complicação rara de uma doença inflamatória abdominal comum

R E S U M O

Palavras-chave:

Apendicite
Apendicectomia
Abdomen agudo
Torção do cordão espermático
Escroto agudo

Introdução: A apendicite aguda é a doença cirúrgica mais comum do abdome na prática clínica, afetando principalmente adultos jovens. Tem uma grande variedade de apresentações clínicas, devido à variação anatômica do apêndice cecal. Sua apresentação como escroto agudo e abscesso escrotal é bastante rara e atípica, ocorrendo principalmente em pacientes jovens do sexo masculino com túnica vaginalis patente.

Apresentação do caso: um paciente do sexo masculino de 18 anos de idade compareceu à unidade de emergência queixando dor abdominal difusa, febre e hiporexia por quatro dias que se seguiram de sinais inflamatórios no escroto. Ele foi levado para centro cirúrgico após o diagnóstico de sepse de origem escrotal e abdominal. Durante a exploração da bolsa escrotal, secreção purulenta foi encontrada do lado direito oriunda do canal inguinal e comunicando-se com a cavidade abdominal. Durante a laparotomia observou-se sinais de apendicite aguda perfurada e peritonite levando ao abscesso escrotal. O abscesso foi drenado, a apendicectomia foi realizada e as cavidades escrotal e abdominal foram lavadas com solução salina. Apesar de complicações pós-operatórias como pneumonia e abscesso intra-abdominal, o paciente recuperou-se bem, recebendo alta hospitalar no 44º dia pós-operatório.

Conclusão: A apendicite aguda pode simular o escroto agudo e os cirurgiões devem ter um alto grau de suspeição dessa complicação para o diagnóstico. Esta apresentação clínica incomum pode ser desafiadora e retardar o diagnóstico levando à peritonite por perfuração.

© 2017 Sociedade Brasileira de Coloproctologia. Publicado por Elsevier Editora Ltda. Este é um artigo Open Access sob uma licença CC BY-NC-ND (<http://creativecommons.org/licenses/by-nc-nd/4.0/>).

Introduction

Acute appendicitis is the most frequent cause of surgical acute abdomen and about 8% of the Western population will develop the disease anytime during life, with peak incidence between 10 and 30 years old.^{1,2} Reginald Fitz, a professor from Harvard, described acute appendicitis in 1886 and was the first one to write about its pathophysiology hypothesis.³

In embryology, the appendix appears around the 8th week of pregnancy. Despite many theories related to the role of the appendix in the immune system and the presence of lymphoid follicles in its submucosa, the appendix still has unknown function in adults. Its length ranges from 2 to 20 cm, average of 9 cm, localized in the convergence of the taenias on the anterior face of the cecum. However, the tip of the appendix varies in its location, being pelvic in 30% of the population.⁴

The small diameter of the appendix in relation to its length facilitates luminal obstruction, which is believed to be the major cause of acute appendicitis. This obstruction may be caused either by fecal stasis and fecaliths, lymphoid hyperplasia, fruit seeds, parasites or neoplasia. The pathophysiology theory suggests that luminal obstruction causes bacterial overgrowth followed by secretion of mucus and intraluminal distention, leading to mucosal ischemia, which may progress to gangrene and perforation of the appendix.⁵ Perforation usually happens after 48 h of inflammatory process and is quickly blocked by adjacent organs and tissues. When free perforation of the appendix occurs it lead to peritonitis, septic shock or multiple intraperitoneal abscesses.^{1,5}

Acute appendicitis is a bacterial infection composed mainly by *Escherichia coli* (70%), *Streptococcus viridans* (43%), *Bacterioides* (80%) and *Pseudomonas* (18%) species often being isolated.⁵

Its initial clinical presentation may be very variable and the most common symptoms are diffuse abdominal pain followed by hyporexia and nausea. Commonly, vomiting may occur and the pain is later located in the lower right quadrant of the abdomen. Patients usually develop fever and leukocytosis. Although most patients manifest paralytic ileus, diarrhea may occasionally occur. Urinary symptoms may be associated when the appendix is in the retrocecal localization close to the ureter.⁶

The diagnosis can be confirmed by abdominal ultrasonography in the majority of cases, in which a thickened appendix (7 mm or more of diameter), non-compressible luminal structure with thickened walls (target lesion) is found. Computed tomography is more accurate in diagnosis and is frequently used in non-typical and elderly presentations.⁷ But, sometimes, only surgical exploration and pathological analysis of the removed appendix can confirm the diagnosis. Elderly patients should be submitted to colonoscopy after the appendectomy (4 weeks), due to the risk of colon neoplasia, identified in approximately 5% of cases in old people.⁸

Appendectomy is still the standard treatment for acute appendicitis.⁹ In the case of uncomplicated appendicitis, a single dose of preoperative antibiotic covering the colonic microbiota is sufficient. But in cases of perforation or gangrene, venous antibiotic therapy should be maintained postoperatively. Most patients with uncomplicated appendicitis are discharged within 24 h.^{10,11}

The most common complication after appendectomy are surgical site infection (1.2–12%), which has low morbidity, followed by intrabdominal abscess (1.6–8%). Bowel obstruction and fistulas are rare complications (0–1.9%). Higher rates of complications are found in patients with appendicitis complicated with peritonitis.⁹

Although clinical history and symptoms of acute appendicitis are well known by surgeons, atypical presentations have been reported and can be challenging. The unusual presentation of acute appendicitis may include backache, left lower quadrant pain, groin pain from a strangulated femoral hernia containing the appendix and other situations due to anatomic anomaly such as malrotation and patent processus vaginalis.¹²

In this article, we present a rare case report of perforated acute appendicitis that mimicked acute scrotal pathology.

Case presentation

A previously healthy male patient from Belo Horizonte (Brazil), 18 years old, reported diffuse abdominal pain, fever and hyporexia for 4 days. Two days later, he started to complain intense right testicular pain, associated with hyperemia and local edema. Diffuse abdominal pain was present after this 6-day history when he finally looked for medical care. There was no report of testicular trauma or urinary symptoms.

This reported patient attended the urgency unit of our hospital with signs of sepsis – fever (38.5°C), pulse rate of 112 per minute, low systemic pressure and tachypnea. On the clinical examination, his scrotum was red and swollen and there was tenderness by direct percussion of the lower abdomen. The skin around the scrotum, mainly in the groin and hypogastric area, was also red and suggests evolution to a Fournier Syndrome (Fig. 1). Testicular torsion could not be excluded at this time. Laboratory tests showed a significant increase of white cell count ($18 \times 10^9/L$) and C-reactive protein of about 260. Intensive care support and antibiotic therapy was immediately started. An ultrasonography of the scrotum was performed, which showed the vascularization of both testicles preserved, an abscess in the right hemiscrotum and the presence of edema in the subcutaneous and in the muscular fascia of the abdominal wall and inguinal region. The abdominal ultrasound demonstrated free liquid in the pelvis but did not find the appendix.

The patient was taken to the operation room for scrotum and abdominal exploration. The surgical procedure was initiated by scrotum exploration and pus was found after the right tunica vaginalis opening coming down from the inguinal canal and communicating with the abdominal cavity. The abscess was drained and the scrotum cavity washed with saline solution. The left hemiscrotum cavity was also explored and there was not pus and nor necrosis inside. A laminar drain was remained in the right hemiscrotum for 3 days.

Afterwards, laparotomy was performed and a perforated retrocecal appendix was found with diffuse peritonitis (Fig. 2). Appendectomy was performed and followed by abdominal cavity wash with saline solution.

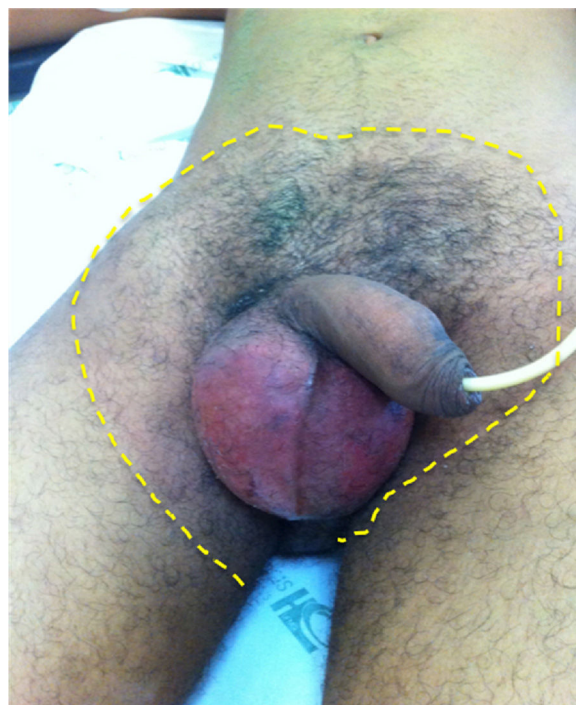

Fig. 1 – Signs of acute scrotum and red skin in the groins and low abdomen suggesting evolution to Fournier Syndrome.

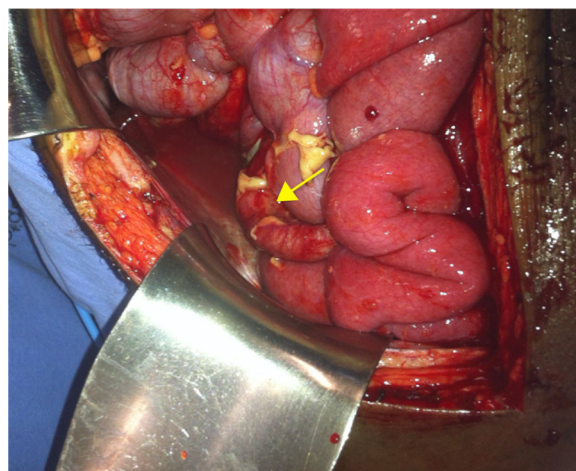


Fig. 2 – Perforated appendix involved with fibrin (arrow).

The patient remained in intensive care unit for 15 days due to sepsis. He developed postoperative infectious complications such as pneumonia, respiratory failure, intra-abdominal abscess, systemic fungal infection and malnutrition. He was treated with systemic antibiotic therapy, percutaneous drainage of the abdominal abscess and nutritional support. He was discharged on the 44th postoperative day after recovering. Pathological examination confirmed acute perforated appendicitis.

Discussion

We reported this unusual clinical presentation of acute appendicitis to highlight the possibility of surgical abdominal intervention when abdominal pain is associated with acute scrotum and the origin of infection was not elucidated during scrotal exploration. It is rare for a non-scrotal pathology to manifest with acute scrotal signs and less than ten cases were described previously.¹³⁻¹⁵ Literature reviews and case reports show that this process mainly affects children and teenagers, preferably males, with patent processus vaginalis and may also occur as a postoperative complication of appendectomy.

The relationship between the scrotum and the abdominal cavity is already well known. The scrotum develops as part of the abdominal cavity and the processus vaginalis remains patent in approximately 80-90% of newborns, decreasing to approximately 20% in adults. The patent processus vaginalis can also lead to hydrocele or congenital inguinal hernia in newborns.¹⁶

Appendicitis and testicular torsion are common general surgical and urological emergencies. Both of these conditions need prompt surgical treatment in the majority of cases as the delay may increase the morbidity and mortality of these conditions. Removal of the source of sepsis, scrotal and abdominal lavages, and antibiotic therapy are keys to successful management.^{16,17} In this case report the patient developed severe complications compatible with sepsis after abdominal peritonitis and he needed prolonged systemic antibiotic therapy.

Acute appendicitis should always be maintained as one of the main diagnostic hypotheses in case of abdominal pain in young adults, aiming the early diagnosis and treatment. In this case report, the acute scrotum occurred due to a delayed diagnosis of the acute appendicitis.

Patients with perforated appendicitis may present symptoms of sepsis, requiring resuscitation and stabilization prior to the surgical procedure. Those who are diagnosed with local abscess may require previous clinical treatment. Small abscesses in stable patients can be conducted with venous antibiotic therapy and elective appendectomy. Major abscesses (more than 6 cm of diameter) in febrile patients should be drained percutaneously or transrectal, and appendectomy performed later, about 6 weeks after the initial inflammatory process.¹⁸⁻²⁰ Andersson et al.¹⁸ demonstrated that early surgical treatment of complicated appendicitis (abscess or phlegmon) was associated with higher morbidity compared to initial conservative treatment (OR 3.3 95% CI 1.9-5.6).¹⁸ Despite the possibility of conservative treatment, most of the surgeons prefer early surgical treatment for all cases when acute appendicitis is the probable diagnosis. There is agreement that rates around 15% of negative appendectomies have to be accepted in order to reduce the rate of morbidity and mortality of acute appendicitis.¹⁸⁻²⁰

The presentation of an acutely tender, red, and swollen scrotum in a young man still leads at first to the probable diagnosis of testicular torsion. Clinical history, careful examination and the presence of other symptoms as abdominal pain and tenderness are keys to detecting atypical presentation, as was demonstrated in this case report.

Conclusion

Acute appendicitis may manifest as acute scrotum, mimicking other pathologies as testicular torsion or incarcerated inguinal hernia. The unusual presentation may be challenging and can delay the diagnosis leading to perforated peritonitis. Since the acute scrotum and the acute appendicitis are very frequent diseases in the surgical emergencies, surgeons must have a high index of suspicion of this complication.

Conflicts of interest

The authors declare no conflicts of interest.

REFERENCES

1. Alvarado A. How to improve the clinical diagnosis of acute appendicitis in resource limited settings. *World J Emerg Surg.* 2016;11:16.
2. Santos FD, Cavasana GF, Campos T. Profile of the appendectomies performed in the Brazilian Public Health System. *Rev Col Bras Cir.* 2017;44:4-8.
3. Williams GR. Presidential Address: a history of appendicitis. With anecdotes illustrating its importance. *Ann Surg.* 1983;197:495-506.
4. Wray CJ, Kao LS, Millas SG, Tsao K, Ko TC. Acute appendicitis: controversies in diagnosis and management. *Curr Probl Surg.* 2013;50:54-86.
5. Petroianu A, Villar Barroso TV. Pathophysiology of acute appendicitis. *JSM Gastroenterol Hepatol.* 2016;4:1062.
6. Debnath J, Sharma V, Ravikumar R, Kumar R, Chatterjee S, Sampath S, et al. Clinical mimics of acute appendicitis: is there any role of imaging? *Med J Armed Forces India.* 2016;72:285-92.
7. Mostbeck G, Adam EJ, Nielsen MB, Claudon M, Clevert D, Nicolau C, et al. How to diagnose acute appendicitis: ultrasound first. *Insights Imaging.* 2016;7:255-63.
8. Cohen-Arazi O, Dabour K, Bala M, Haran A, Almogy G. Management, treatment and outcomes of acute appendicitis in an elderly population: a single-center experience. *Eur J Trauma Emerg Surg.* 2017;43:723-7.
9. Gorter RR, Eker HH, Gorter-Stam MA, Abis GS, Acharya A, Ankersmit M, et al. Diagnosis and management of acute appendicitis. EAES consensus development conference 2015. *Surg Endosc.* 2016;30:4668-90.
10. Jimbo T, Masumoto K, Takayasu H, Shinkai T, Urita Y, Uesugi T, et al. Outcome of early discharge protocol after appendectomy for pediatric acute appendicitis. *Pediatr Int.* 2017;59:803-6.
11. Rosen DR, Inaba K, Oh PJ, Gutierrez AC, Strumwasser AM, Biswas S, et al. Outpatient laparoscopic appendectomy: feasible in a public county hospital? *J Am Coll Surg.* 2017, pii:S1072-7515(17)30181-3.
12. Singla AA, Rajaratnam J, Singla AA, Wiltshire S, Kwik C, Smigelski M, et al. Unusual presentation of left sided acute appendicitis in elderly male with asymptomatic midgut malrotation. *Int J Surg Case Rep.* 2015;17:42-4.
13. Satchithananda K, Beese RC, Sidhu PS. Acute appendicitis presenting with a testicular mass: ultrasound appearances. *Br J Radiol.* 2000;73:780-2.
14. Luchtman M, Kirshon M, Feldman M. Neonatal pyosrotum and perforated appendicitis. *J Perinatol.* 1999;19:536-7.

15. Friedman SC, Sheynkin YR. Acute scrotal symptoms due to perforated appendix in children: case report and review of literature. *Pediatr Emerg Care*. 1995;11:181-2.
16. Ceresoli M, Zucchi A, Allievi N, Harbi A, Pisano M, Montori G, et al. Acute appendicitis: epidemiology, treatment and outcomes – analysis of 16544 consecutive cases. *World J Gastrointest Surg*. 2016;8:693-9.
17. Ta A, D’Arcy FT, Hoag N, D’Arcy JP, Lawrentschuk N. Testicular torsion and the acute scrotum: current emergency management. *Eur J Emerg Med*. 2016;23:160-5.
18. Andersson RE, Petzold MG. Nonsurgical treatment of appendiceal abscess or phlegmon: a systematic review and meta-analysis. *Ann Surg*. 2007;246:741-8.
19. Luo CC, Cheng KF, Huang CS, Lo HC, Wu SM, Huang HC, et al. Therapeutic effectiveness of percutaneous drainage and factors for performing an interval appendectomy in pediatric appendiceal abscess. *BMC Surg*. 2016;16:72.
20. Mason RJ, Moazzez A, Sohn H, Katkhouda N. Meta-analysis of randomized trials comparing antibiotic therapy with appendectomy for acute uncomplicated (no abscess or phlegmon) appendicitis. *Surg Infect (Larchmt)*. 2012;13:74-84.