



Original Article

Continence changes following transanal endoscopic microsurgery result from the impact on rectal capacity: clinical and functional evaluation before and after surgical treatment



Carlos Ramon Silveira Mendes^{a,b,c,d}, Sergio Eduardo Alonso Araujo^e, Rodrigo Perez^f, Ivan Ceconello^f, Luiz Augusto Carneiro D'Albuquerque^f

^a Hospital Santa Izabel, Serviço de Coloproctologia, São Paulo, SP, Brazil

^b Sociedade Brasileira de Coloproctologia, Rio de Janeiro, RJ, Brazil

^c Hospital Cardio Pulmonar, Serviço de Coloproctologia, Salvador, BA, Brazil

^d Hospital Geral Roberto Santos, Serviço de Coloproctologia, Salvador, BA, Brazil

^e Hospital Albert Einstein, São Paulo, SP, Brazil

^f Universidade de São Paulo, Faculdade de Medicina, São Paulo, SP, Brazil

ARTICLE INFO

Article history:

Received 28 April 2018

Accepted 6 May 2018

Available online 5 June 2018

Keywords:

Rectal neoplasms

Fecal incontinence

Transanal endoscopic microsurgery

Rectal diseases

Colorectal neoplasms

ABSTRACT

Introduction: Described in 1983 and with a stable clinical application, the impact of Transanal Endoscopic Microsurgery on anorectal function remains unknown. The objectives of the present study were to evaluate the impact of Transanal Endoscopic Microsurgery on anorectal function according to clinical (Wexner score) and functional (anorectal manometry) evaluations before and after surgery.

Method: Prospectively, 23 consecutive patients with rectal lesions were operated using TEO[®] equipment (Karl Storz, Tuttlingen, Germany). For all patients, the value of Wexner score was obtained before and after surgery (7, 30 and 90 days) and anorectal electromanometry was performed before surgery, and also postoperatively (30 and 90 days).

Results: Fourteen patients were men. The mean age was 53.7 (24–81) years. The mean distance from the lesion to the pectineal line was 7 (2–15) cm. The histopathologic analysis revealed adenoma in 14 (61%); neuroendocrine tumor in 5 (21.7%); invasive carcinoma in 3 (13%); and hyperplastic polyp in 1 (4.3%) case. The mean duration of postoperative follow-up was 5 (3–7) months. Wexner score was significantly lower at 30 days compared to 7 days (Wilcoxon; $p = 0.03$). Rectal capacity was significantly lower 30 days after surgery and recovered at 90 days of surgery (ANOVA; $p = 0.04$).

E-mail: proctoramom@hotmail.com (C.R. Mendes).

<https://doi.org/10.1016/j.jcol.2018.05.005>

2237-9363/Published by Elsevier Editora Ltda. on behalf of Sociedade Brasileira de Coloproctologia. This is an open access article under the CC BY-NC-ND license (<http://creativecommons.org/licenses/by-nc-nd/4.0/>).

Conclusions: After Transanal Endoscopic Microsurgery, a modest impact on anorectal function can be observed. The transient impairment results from loss of rectal capacity and not from impairment of the anal sphincters, being completely resolved 90 days after surgery.

Published by Elsevier Editora Ltda. on behalf of Sociedade Brasileira de Coloproctologia.

This is an open access article under the CC BY-NC-ND license (<http://creativecommons.org/licenses/by-nc-nd/4.0/>).

Alterações da continência após microcirurgia endoscópica transanal resultam do impacto sobre a capacidade retal: avaliação clínica e funcional antes e após tratamento cirúrgico

R E S U M O

Palavras-chave:

Neoplasias retais
Incontinência fecal
Microcirurgia endoscópica transanal
Doenças retais
Neoplasias colorretais

Introdução: Descrita em 1983 e de sólida aplicação clínica, o impacto da Microcirurgia Endoscópica Transanal sobre a função anorretal permanece pouco conhecido. Os objetivos do presente estudo foram avaliar o impacto da Microcirurgia Endoscópica Transanal na função anorretal conforme avaliações clínica (Wexner score) e funcional (manometria anorretal) antes e após a cirurgia.

Método: Prospectivamente, 23 pacientes consecutivos com lesões retais foram operados com o uso do equipamento TEO® (Karl Storz, Tuttlingen, Alemanha). Para todos os pacientes, o valor do escore de Wexner foi obtido antes e após a cirurgia (7, 30 e 90 dias) e a eletromanometria anorretal foi realizada antes da cirurgia e também no pós-operatório (30 e 90 dias).

Resultados: Quatorze pacientes eram homens. A idade média foi 53,7 (24–81) anos. A distância média da lesão à linha pectínea foi de 7 (2–15) cm. A histopatológica revelou adenoma em 14 (61%), tumor neuroendócrino em 5 (21,7%); carcinoma invasivo em 3 (13%) e pólipos hiperplásicos em 1 (4,3%) caso. A duração média do seguimento pós-operatório foi de 5 (3–7) meses. O escore de Wexner foi significativamente menor aos 30 dias em comparação com 7 dias (Wilcoxon; $p=0,03$). A capacidade retal foi significativamente menor aos 30 dias após a cirurgia e recuperada aos 90 dias após a cirurgia (ANOVA; $p=0,04$).

Conclusões: Após Microcirurgia Endoscópica Transanal, um impacto modesto na função anorretal pode ser observado. O comprometimento transitório resulta de perda de capacidade retal e não por comprometimento dos esfíncteres anais cessando completamente 90 dias após a cirurgia.

Publicado por Elsevier Editora Ltda. em nome de Sociedade Brasileira de Coloproctologia. Este é um artigo Open Access sob uma licença CC BY-NC-ND (<http://creativecommons.org/licenses/by-nc-nd/4.0/>).

Introduction

Transanal Endoscopic Microsurgery (TEM) was introduced in 1983 by Gerhard Friederik Buess, in Germany, as a minimally invasive technique for surgical resection of adenomas and early rectal carcinomas¹ in a time prior to video surgery, single portal videosurgery, and surgery through natural orifices (NOTES, from Natural Orifice Transanal Endoscopic Surgery). Developed after the association between Buess and the Richard Wolf (Richard Wolf, GmbH, Knittlingen, Germany) Medical Instrument Company, TEM was introduced slowly. For many years, all publications on the new technique described technical aspects of the operation and sought to convince the community of colorectal surgeons about the possible simplicity of the method.^{2–4} This does not seem necessarily true if the birth of a revolutionary surgery technique in an era of pre-video surgery is contemplated. This, in our opinion, proves Buess's geniality and resilience. He died on October 30, 2010 and, as stated by Sir Alfred Cuschieri, was "a man ahead of his

time". As a result of the relative technical complexity and initial direct cost associated with the acquisition of equipment designed exclusively to perform transanal endoscopic surgery, it is correct to state that, for almost 30 years, TEM has experienced more criticism than allusions to its revolutionary nature as the only NOTES gatekeeper.

With the advent of the Transanal Endoscopic Operations (TEO®) platform for transanal endoscopic surgery launched by Karl Storz (Tuttlingen, Germany), a new leap in transanal surgery took place in the world and in our field. In the TEO platform, the use of specific instruments was still necessary for transanal surgery, but usable in association with a conventional video-surgery system available in surgical centers of general hospitals. A new revolution in transanal endoscopic surgery would result from the introduction of the Transanal Minimally Invasive Surgery (TAMIS) technique in 2009, as an alternative to the TEM/TEO systems by Atallah et al.^{5,6} These latter reported the feasibility of using a device of single, flexible and disposable transanal portal, allowing the use of common laparoscopic instruments to perform the resection of rectal

lesions. As a frontier of the evolution of transanal surgery, the results of the use of single-portal robotic systems to perform transanal endoscopic surgery are expected to definitively solve the challenge of the lack of triangulation during endoscopic endorectal surgery.

TEM assumes the transanal insertion of a surgical rectoscope of 40 mm in diameter. In addition, the rectal lesion is usually excised at full thickness of the wall leading to a varying degree of rectal reservoir reduction. As a result, the hypothesis that due to prolonged anal dilation during TEM, anal sphincter function could be at risk has prevailed for many years.^{7,8} However, few studies have addressed the functional outcome after TEM. In addition, these studies were performed in patients with different medical indications, and used different methodologies and variables with noncomparable results.⁸⁻¹² As a result, in some studies, there is evidence of a temporary impact on anorectal function,^{8,10} while in others, anorectal function is monotonously preserved after TEM,^{9,11,12} which made it difficult to accurately predict the impact on the anal continence for a given patient in clinical practice with indication of TEM.

In light of the above, in the present study we sought to evaluate the impact of TEM on anorectal function through clinical and functional evaluation before and after surgery.

Patients and methods

This is a prospective study, approved by the Institutional Ethics Committee. After the application of written informed consent, consecutive patients with indication for TEM were recruited between January 2013 and December 2014.

Inclusion criteria were: indication of resection of rectal lesions through TEM (benign and potentially malignant lesions located up to 15 cm from the anal canal), absence of preoperative clinical diagnosis of anal incontinence, and complete understanding of the informed consent term.

Exclusion criteria were the refusal to participate in the study, presence of continence disorder, history of surgery for anal fistula, rectal neoplasia, pelvic radiotherapy, and contraindication for the use of Anorectal Electrophysiology (EMN-AR).

All patients underwent a complete proctologic evaluation, including digital rectal examination, anoscopy, and colonoscopy. In all cases, a complete clinical preoperative evaluation was obtained. For cases of suspected or diagnosed invasive adenocarcinoma, the pre-treatment investigation included rectal magnetic resonance imaging, tomography of the abdomen and thorax, and serum levels of carcinoembryonic antigen (CEA).

Twenty-three patients were included. All were attended at the outpatient's clinic before and after the surgical treatment. In all patients included in the study, clinical and functional evaluations were performed before and after surgery (Fig. 1).

Patient and lesion variables

The variables of the patients and lesions characterized in the present study were: gender, age, Body Mass Index (BMI), previous anorectal surgery, lesion size (before formalin fixa-

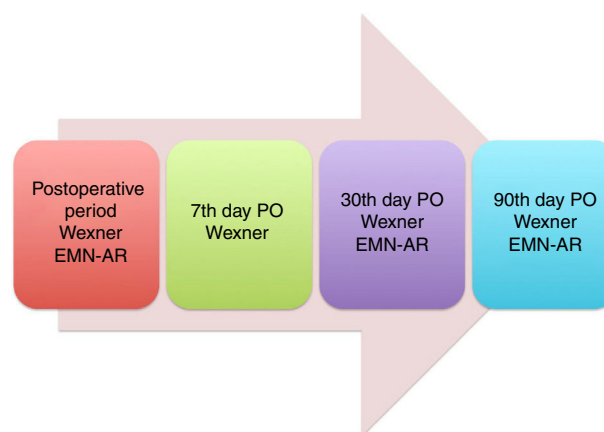


Fig. 1 – Clinical and functional evaluations before and after surgery. PO, postoperative.

tion), distance between the lower limit of the lesion and the pectineal line determined by rigid rectoscopy, previous vaginal delivery, and type of transanal microsurgical endoscopic resection (if partial or total thickness).

Surgical procedure

All patients received complete antegrade bowel preparation and parenteral antibiotic prophylaxis. In all cases, the TEM surgical procedure was performed by a single surgeon.

General anesthesia was used in all cases. For patients with lesions that were not reached with digital exam, rigid rectosigmoidoscopy was performed after anesthesia to locate the lesion. The patient was placed in the supine, lateral or prone position, depending on the location of the lesion.

The TEO[®] system (Transanal Endoscopic Operations, Karl Storz, Tuttlingen, Germany) was used in all cases. Rectal wall resections of full or partial thickness were performed. Partial thickness resections were performed for patients with lesions with no evidence of submucosal invasion. The defect was closed in all cases of total thickness excision.

The diet was offered after discharge from the post-anesthetic recovery unit. Patients were routinely discharged on the first day after surgery.

Clinical evaluation (Wexner score)

Wexner score¹³ was determined prior to surgery and repeated postoperatively after 7, 30, and 90 days.

Functional evaluation (EMN-AR)

For the functional evaluation, EMN-AR was chosen.

EMN-AR was performed in the preoperative period and on the 30th and 90th postoperative day. The same researcher conducted all the exams.

The preparation for the exam included the use of two units of sorbitol/laurisulfate enemas. EMN-AR was performed using a 12-Fr catheter with an 8-channel computerized perfusion system and a 60-mm long balloon located 10 mm from the distal tip of the catheter. The manual withdrawal technique

Table 1 – Casuistry (patients).

Characteristics	Result
N	23
Men, n (%)	14 (61)
Median age, years (range)	53.7 (24–81)
Median body mass index (BMI), kg/m ² (range)	24.9 (18–33)
Distance (median) between the lesion and pectin line, cm (range)	7 (2–15)
Previous anorectal surgery	
None, n (%)	21 (91.3)
Hemorrhoidectomy, n (%)	2 (8.7)

was used at 1-cm intervals with patients on left lateral position. The measures evaluated were: Resting Pressure (RP) and Contraction Pressure (CP) in mmHg, rectal sensitivity (RS) and Rectal Capacity (RC) in mL.

Statistical analysis

The collected data were analyzed using the SPSS statistical package for Windows version 17.0. Values of $p < 0.05$ were considered statistically significant.

To verify if there was a significant difference between the clinical and functional variables over time, a variance analysis (ANOVA) was used with repeated measurements for anorectal manometry data.

For the clinical results (Wexner's score), we used Wilcoxon non-parametric (Signed-rank) test. Both tests considered that the same patient was evaluated more than once.

Results

Patients

Between January 2013 and December 2014, 23 consecutive patients were included in the study. Pre- and postoperative clinical and functional evaluations could be performed in all patients. Clinical-demographic characteristics of patients are shown in [Table 1](#).

Surgical and histopathological results

Each patient included had only one rectal lesion.

The mean operating time was 53.2 (22–110) min ([Table 2](#)).

Regarding surgical wound closure after resection, it was performed in 22 (95.7%) patients. In 1 (4.3%) case of resection of partial thickness, the wound was left open due to its large extension.

Full thickness resection was performed in 18 (78.3%) cases and partial thickness in 5 (21.7%) cases.

In the series, there was only 1 (4.3%) intraoperative complication. In this patient, bleeding occurred after the end of total thickness excision and was controlled with monopolar electrocoagulation.

Postoperative complications occurred in 3 (13%) cases. The surgical wound separation was diagnosed in 2 (8.7%) patients

Table 2 – Surgical and histopathological results.

Characteristic	Result
Surgical time (median), min (range)	53.2 (22–110)
Type of resection	
Full thickness, n (%)	18 (78.3)
Partial thickness, n (%)	5 (21.7)
Defect closure	
Yes, n (%)	22 (95.7)
No, n (%)	1 (4.3)
Intraoperative complications	
Bleeding, n (%)	1 (4.3)
None, n (%)	22 (95.7)
Postoperative complications	
Wound separation, n (%)	2 (8.7)
Atrial fibrillation, n (%)	1 (4.3)
None, n (%)	20 (87)
Hospital stay (median), days (range)	1.1 (1–4)
Lesion size (median), cm (range)	3.5 (1–8)
Final histopathological diagnosis	
Adenoma, n (%)	14 (61)
Invasive carcinoma, n (%)	3 (13)
Carcinoid tumor, n (%)	5 (22)
Hyperplastic polyp, n (%)	1 (4)

Table 3 – Results of clinical evaluation (Wexner score).

Clinical evaluation	Moment	Median (range)	p (Wilcoxon)
Wexner score	Preoperative	0.44 (0–2)	0.03
	7th day PO	0.61 (0–2)	
	30th day PO	0.35 (0–2)	
	90th day PO	0.35 (0–1)	
PO, postoperative.			

and 1 (4.3%) patient developed atrial fibrillation in the immediate postoperative period, being successfully treated.

No patient was converted to laparoscopy and anterior resection of the rectum. There was no need for reoperation or readmissions. The mean duration of hospitalization was 1.1 (1–4) days. The median duration of postoperative follow-up was 5 (3–7) months.

The mean size of the rectal lesion was 3.5 (1–8) cm. No specimens were fragmented. The final histopathological diagnosis was adenoma in 14 (61%) cases, carcinoid tumor in 5 (22%), invasive adenocarcinoma in 3 (13%) and hyperplastic polyp in 1 (4%) patient. There were no involved margins. All 3 patients with invasive carcinoma had lesions classified as pT1 at the final histopathological examination. All lesions were resected with wide lateral and deep safety margins. Patients with invasive rectal carcinoma (pT1) were selected for exclusive local resection with curative intent and were routinely screened postoperatively.

Results of medical evaluation (Wexner score)

Wexner score results obtained in the preoperative period and 7, 30 and 90 days after TEM are shown in [Table 3](#). The (median) results of Wexner score were significantly higher on the 7th postoperative day compared to the 90th postoperative day ($p = 0.03$ – Wilcoxon's test).

Table 4 – Results of functional evaluation (EMN-AR).

Variable	Moment	Median (range)	p (ANOVA)
RP (mmHg)	Preoperative	64.7 (27.5–104)	0.06
	30th day PO	60.4 (19.1–100)	
	90th day PO	65.4 (26.2–103.1)	
CP (mmHg)	Preoperative	129.6 (65.7–293.7)	0.25
	30th day PO	123.5 (53.3–266.5)	
	90th day PO	135.1 (56.9–274)	
RS (mL)	Preoperative	30 (10–80)	0.29
	30th day PO	30 (10–60)	
	90th day PO	20	
RC (mL)	Preoperative	120	0.04
	30th day PO	100	
	90th day PO	130	

EMN-AR, anorectal electromanometry; RP, rest pressure; CP, contraction pressure; RS, rectal sensitivity; RC, rectal capacity; PO, postoperative.

Functional results (EMN-AR)

Although there was a tendency to the reduction of RP 30 days after TEM and recovery to the initial results observed on the 90th postoperative day, median RP before and after TEM was not significantly different in this study (ANOVA, $p = 0.06$). There were no significant differences in mean values for CP (ANOVA; $p = 0.25$) and median RS (ANOVA, $p = 0.29$) between the preoperative period, 30 and 90 days after TEM. In relation to RC, a significant reduction of the median values was observed on the 30th day after TEM, and recovery to values similar to those of the preoperative period at 90 days of surgery (ANOVA; $p = 0.04$) (Table 4).

Discussion

Since its introduction by Buess and colleagues in 1983 (1), a considerable number of studies have confirmed the efficacy and safety of TEM for treating benign and early malignant rectal lesions. However, more than 30 years after the procedure, functional and postoperative quality of life outcomes are still addressed by a few retrospective studies with a small sample size, covering different lesions of variable sizes and using several variables that are not always comparable to evaluate anorectal function after TEM.^{9,14–17} For example, in some of these studies, different scores were considered for clinical evaluation, variables were obtained only in the postoperative period and, finally, at different times of postoperative follow-up. These difficulties represent the main obstacles to conceive, even today, the actual impact of TEM on postoperative anorectal function.

In the present prospective study in 23 consecutive patients undergoing TEM, a modest but significant impact on the clinical and functional outcomes of anorectal function could be detected. Although there is a concern about the possibility of sphincter damage associated with the diameter of the surgical anoscope used in TEM,^{8,10,12} we observed that the impairment of anorectal function was not due to sphincter dysfunction, but due to the reduction of rectal capacity after the surgery.

As some authors¹⁸ understand that a reproducible clinical evaluation of the anorectal function with sufficient specificity and sensitivity is not yet available, how incontinence should be assessed clinically remains controversial. Although there are still concerns about reliability, several clinical tools are available and the most widely used is the Wexner score (13). However, Cataldo and colleagues (17) preferred to validate the number of bowel movements per day and the ability to postpone defecation as clinical variables because of their objective nature and because they are not directly measured in validated incontinence research. Regarding the impact of TEM on clinically evaluated anal function, some studies agree that TEM does not have a significant clinical impact on the anorectal function,^{12,16,18,19} while other authors have found a temporary impact on continence.^{7,8,11,14,15,20,21} In the present study, mean Wexner score results were significantly higher on day 7 when compared to the 90th postoperative day. Therefore, it is possible to measure some impact on early anal continence after TEM. Our experience confirms the temporary nature of this impairment when an adequate prospective evaluation is used allowing comparison with the clinical results before surgery. The next logical step would be to use the current available functional investigation (such as the EMN-AR) to try to define the cause of the clinical impact of TEM on continence. Historically, several authors^{22–24} have published findings of anal sphincter impairment following anal dilatation or after the use of surgical anal dilators during anorectal surgeries. In these studies, morphological findings that are consistent with anal sphincter lesion were reported. However, in these same studies, sphincter function was not evaluated together. In addition, several authors reported a significant decrease in RP and CP values after TEM.^{8,9,11,12,14,18,20,21,25} In our study, a reduction in RP (of 64.7–60.4 mmHg – median) and CP (from 129.3 to 123.5 – median) values after TEM could be measured, although they were not statistically significant. These results can be explained by our small series of cases and also by the hypothesis that a stable and controlled anal dilatation is used during TEM. On the other hand, in this series, with regard to rectal capacity, a significant reduction in mean values was observed on the 30th day after TEM, followed by recovery to mean values similar to baseline values 90 days after surgery. If we consider that in this study the mean size of the removed rectal lesion was 3.5 cm, it seems reasonable to consider the impact of TEM on rectal capacity as remarkable and, therefore, its clinical impact on anorectal function.

In the present study, clinical evaluation (Wexner's score), and the EMN-AR variables were collected before and after surgery. However, we recognize some limitations of our work. A small sample size remains an important feature of our study as well. The limited duration of post-TEM follow-up may be another important limitation, even though the impact on the anorectal function observed in the present study is absolutely temporary and modest. Finally, it may be important to note that in this study, the lesions removed through TEM were not large, because cases of very large lesions or circumferences in which resection and suture could significantly reduce the diameter or rectal capacity were not recruited.

Our study is consistent with current evidence on anorectal function following TEM. TEM did not result in a significant negative impact on fecal continence in most patients. On the

other hand, as this result is based on a small series of cases, larger trials are needed. Some authors defend the inclusion of patients with pre-TEM anal continence impairment. We respectfully disagree. Finally, to include larger lesions seems to be a necessity, in order to provide better evidence on the adequate use of TEM in patients with rectal lesions; it would not be to determine the existence of impact on continence, since it definitely seems to occur, but rather to determine the time required to full or partial recovery of the anorectal function, and which variables are associated with the quality of this recovery.

Conflicts of interest

The authors declare no conflicts of interest.

REFERENCES

- Buess G, Theiss R, Hutterer F, Pichlmaier H, Pelz C, Holfeld T, et al. Transanal endoscopic surgery of the rectum – testing a new method in animal experiments. *Leber Magen Darm*. 1983;13:7–37.
- Buess G, Theiss R, Günther M, Hutterer F, Pichlmaier H. Endoscopic surgery in the rectum. *Endoscopy*. 1985;17:31–5.
- Buess G. Microscopic endoscopic tumor surgery. What is possible? *Langenbecks Arch Chir Suppl II Verhandlungen Dtsch Ges Chir Dtsch Ges Chir Kongr*. 1989: 553–9.
- Buess G, Kipfmüller K, Hack D, Grüssner R, Heintz A, Junginger T. Technique of transanal endoscopic microsurgery. *Surg Endosc*. 1988;2:71–5.
- Atallah S, Albert M, Larach S. Transanal minimally invasive surgery: a giant leap forward. *Surg Endosc*. 2010;24:2200–5.
- Atallah SB, Albert MR, deBeche-Adams TH, Larach SW. Robotic transanal minimally invasive surgery in a cadaveric model. *Tech Coloproctol*. 2011;15:461–4.
- Dafnis G, Pählman L, Raab Y, Gustafsson U-M, Graf W. Transanal endoscopic microsurgery: clinical and functional results. *Colorectal Dis Off J Assoc Coloproctol G B Irel*. 2004;6:336–42.
- Herman RM, Richter P, Walega P, Popiela T. Anorectal sphincter function and rectal barostat study in patients following transanal endoscopic microsurgery. *Int J Colorectal Dis*. 2001;16:370–6.
- Allaix ME, Rebecchi F, Giaccone C, Mistrangelo M, Morino M. Long-term functional results and quality of life after transanal endoscopic microsurgery. *Br J Surg*. 2011;98:1635–43.
- Kreis ME, Jehle EC, Haug V, Manncke K, Buess GF, Becker HD, et al. Functional results after transanal endoscopic microsurgery. *Dis Colon Rectum*. 1996;39:1116–21.
- Banerjee AK, Jehle EC, Kreis ME, Schott UG, Claussen CD, Becker HD, et al. Prospective study of the proctographic and functional consequences of transanal endoscopic microsurgery. *Br J Surg*. 1996;83:211–3.
- Kennedy ML, Lubowski DZ, King DW. Transanal endoscopic microsurgery excision: is anorectal function compromised? *Dis Colon Rectum*. 2002;45:601–4.
- Jorge JM, Wexner SD. Etiology and management of fecal incontinence. *Dis Colon Rectum*. 1993;36:77–97.
- Gracia Solanas JA, Ramírez Rodríguez JM, Aguilera Diago V, Elía Guedea M, Martínez Díez M. A prospective study about functional and anatomic consequences of transanal endoscopic microsurgery. *Rev Espanola Enfermedades Dig Organo Of Soc Espanola Patol Dig*. 2006;98:234–40.
- Doornebosch PG, Gosselink MP, Neijenhuis PA, Schouten WR, Tollenaar RA, de Graaf EJ. Impact of transanal endoscopic microsurgery on functional outcome and quality of life. *Int J Colorectal Dis*. 2008;23:709–13.
- Cataldo PA, O'Brien S, Osler T. Transanal endoscopic microsurgery: a prospective evaluation of functional results. *Dis Colon Rectum*. 2005;48:1366–71.
- Valsdottir EB, Yarandi SS, Marks JH, Marks GJ. Quality of life and fecal incontinence after transanal endoscopic microsurgery for benign and malignant rectal lesions. *Surg Endosc*. 2014;28:193–202.
- Mora López L, Serra Aracil X, Hermoso Bosch J, Rebasa P, Navarro Soto S. Study of anorectal function after transanal endoscopic surgery. *Int J Surg*. 2015;13:142–7.
- Planting A, Phang PT, Raval MJ, Brown CJ. Transanal endoscopic microsurgery: impact on fecal incontinence and quality of life. *Can J Surg*. 2013;56:243–8.
- Zhang H-W, Han X-D, Wang Y, Zhang P, Jin Z-M. Anorectal functional outcome after repeated transanal endoscopic microsurgery. *World J Gastroenterol*. 2012;18:5807–11.
- Jin Z, Yin L, Xue L, Lin M, Zheng Q. Anorectal functional results after transanal endoscopic microsurgery in benign and early malignant tumors. *World J Surg*. 2010;34:1128–32.
- Speakman CT, Burnett SJ, Kamm MA, Bartram CI. Sphincter injury after anal dilatation demonstrated by anal endosonography. *Br J Surg*. 1991;78:1429–30.
- MacDonald A, Smith A, McNeill AD, Finlay IG. Manual dilatation of the anus. *Br J Surg*. 1992;79:1381–2.
- Van Tets WF, Kuijpers JH, Tran K, Mollen R, van Goor H. Influence of Parks' anal retractor on anal sphincter pressures. *Dis Colon Rectum*. 1997;40:1042–5.
- Au-Yong I, Rowsell M, Hemingway DM. Randomised controlled clinical trial of stapled haemorrhoidectomy vs conventional haemorrhoidectomy; a three and a half year follow up. *Colorectal Dis*. 2004;6:37–8.