



## Case Report

# Common operation, uncommon complication. Bleeding from superior haemorrhoidal artery after minimally invasive procedure for hemorrhoids – a case report

Janavikula Sankaran Rajkumar, Aluru Jayakrishna Reddy\*, Ravikumar Radhakrishnan,  
Anirudh Rajkumar, Syed Akbar, Dharmendra Kollapalayam Raman

Life Line Institute of Minimal Access Surgery, Kilpauk, India

### ARTICLE INFO

#### Article history:

Received 7 August 2018

Accepted 5 September 2018

Available online 5 October 2018

#### Keywords:

MIPH

Embolized: pseudoaneurysm

#### Palavras-chave:

PMIH

Embolizadas: pseudoaneurisma

### ABSTRACT

Minimally invasive procedure for hemorrhoids is one of the commonest new wave operations done for prolapsed hemorrhoids. The diameter of the stapled tissue is critical in this operation, and an increase in the same could include more tissue in the anvil, with disastrous results. This is a case report of a post minimally invasive procedure for hemorrhoids bleed, which was refractory to two local oversewing attempts. When the bleeding was massive, an angiogram was obtained. This revealed a pseudo aneurysm of the left superior haemorrhoidal artery, which was embolized, stopping the bleed. The stapler dimensions were studied and the possible cause of the event was arrived at. The specific stapler used had a diameter of 2 mm more than the regular Medtronic and Ethicon staplers, possibly including more of the rectal wall, and the superior haemorrhoidal artery as well. This case report documents a rare and potentially fatal complication of a simple procedure.

© 2018 Sociedade Brasileira de Coloproctologia. Published by Elsevier Editora Ltda. This is an open access article under the CC BY-NC-ND license (<http://creativecommons.org/licenses/by-nc-nd/4.0/>).

### Operação comum, complicação incomum. Sangramento de artéria hemorroidária superior após PMIH – um relato de caso

### RESUMO

O procedimento minimamente invasivo para as hemorroidas (PMIH) é uma das novas operações mais comuns para ao tratamento de hemorroidas prolapsadas. O diâmetro do tecido grampeado é crítico nessa operação; um aumento nesse diâmetro poderia colocar mais tecido na bigorna do grampeador, com resultados desastrosos. Este relato de caso descreve o desfecho de uma hemorragia após PMIH, refratária a duas tentativas locais de

\* Corresponding author.

E-mail: [doc.jk@yahoo.in](mailto:doc.jk@yahoo.in) (A.J. Reddy).

<https://doi.org/10.1016/j.jcol.2018.09.005>

2237-9363/© 2018 Sociedade Brasileira de Coloproctologia. Published by Elsevier Editora Ltda. This is an open access article under the CC BY-NC-ND license (<http://creativecommons.org/licenses/by-nc-nd/4.0/>).

sobressutura. Um angiograma foi realizado quando a hemorragia foi considerada intensa. O exame revelou um pseudoaneurisma da artéria hemorroidária superior esquerda, que foi embolizada, interrompendo o sangramento. As dimensões do grampeador foram estudadas e descobriu-se a possível causa do evento. O grampeador específico usado tinha um diâmetro 2 mm maior do que os grampeadores regulares da Medtronic e da Ethicon e possivelmente captou uma área maior da parede retal e a artéria hemorroidária superior. Este relato de caso documenta uma complicação rara e potencialmente fatal de um procedimento simples.

© 2018 Sociedade Brasileira de Coloproctologia. Publicado por Elsevier Editora Ltda. Este é um artigo Open Access sob uma licença CC BY-NC-ND (<http://creativecommons.org/licenses/by-nc-nd/4.0/>).

## Introduction

The minimally invasive procedure for hemorrhoids or MIPH has made significant strides in the field of proctology.

The principle of this operation is to remove a doughnut of haemorrhoidal tissue from an area above the dentate line, and reposit the anal columns in such a way that the staple line is above the dentate line. This supradentate hemorrhoidopexy is of proven immediate postoperative benefit in the treatment of grade 4 hemorrhoids,<sup>1</sup> doughnut pattern of hemorrhoids, etc. This case report is one of a 27-year old male who underwent the MIPH and had severe postoperative bleeding, found to be pseudo aneurysmal in origin. Emergency angioembolisation was therapeutic.

## Case report

A 27-year old had MIPH for Grade 3 hemorrhoids, in a circumferential presentation. He underwent the procedure using a newer version of the MIPH gun, available in the Indian market. Made in China, the gun looked identical to the standard guns from Ethicon, and functioned identically *ex vivo*.

The procedure was straightforward, with a purse string up to the internal sphincter, but excluding it and the final staple line was 3 cm above the dentate line.

On the second post-operative day, along with the stools, there was a large bleed per rectum. Conservative management was adopted, but on the third post operative day, there was a massive bleed, and a drop of hemoglobin of 3 g, necessitating transfusion of three units of packed red cells, and an exploration of the staple line, which was found to have a brisk arterial spurter. This was oversewn, along with the stapler line, using 2/0 polyglactin sutures (vicryl). After 48 h, he had one more bout of bright red blood issuing from the anus, and once more had transfusions and exploration. The staple line bleed was at the same spot, in the 3-o'clock position. Deep sutures of 2/0 vicryl were again deployed. For the next 48 h he was stable, and consequently discharged.

He was readmitted; barely 12 h later, with a massive rebleed, and was hypotensive.

After aggressive resuscitation with intravenous fluids, packed cells, and fresh frozen plasma, a decision was taken to study the vascular anatomy locally in a more detailed manner. To this end, an angiogram of the internal iliac artery

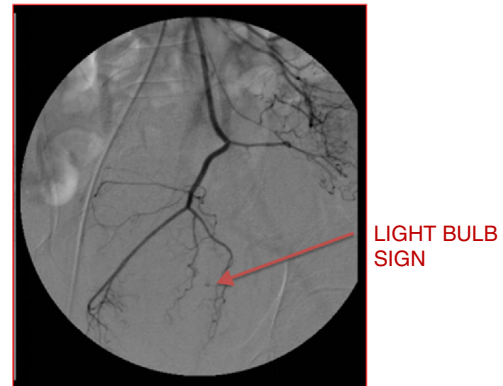


Fig. 1 – Superior rectal artery – light bulb sign.

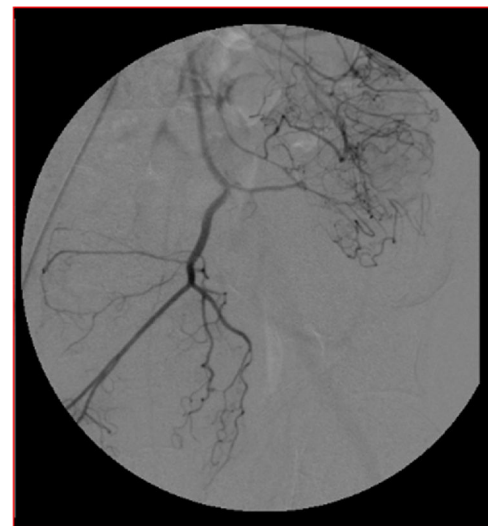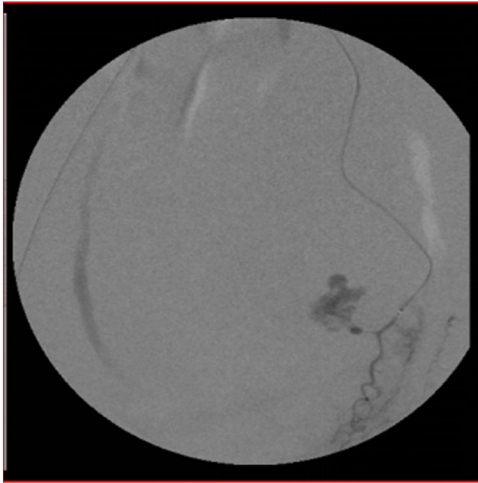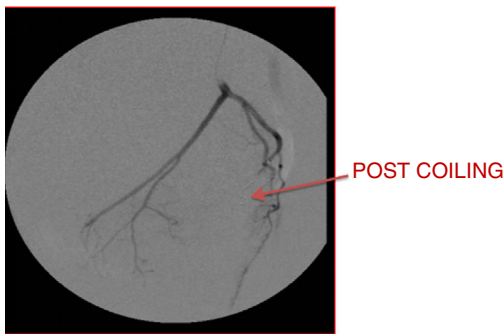


Fig. 2 – Inferior mesenteric artery (IMA) angiogram.

was obtained, which showed a pseudo aneurysm of the left superior haemorrhoidal artery, with active leak of contrast, signifying an ongoing bleed, known as the light bulb sign (Fig. 1). Immediate embolization was completed, with sealing of the contrast leak immediately demonstrated (Figs. 2–4). Thereafter, the patient had a smooth postoperative course, with no further complications.



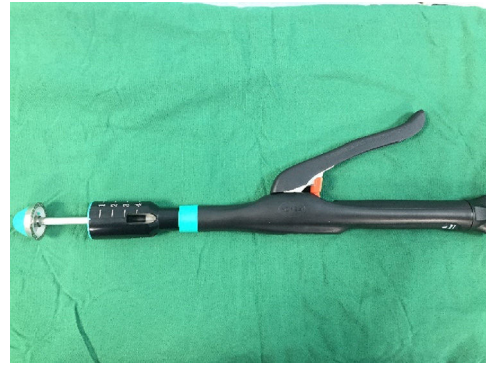**Fig. 3 – Super selective angiogram-active extravasation contrast.**



**Fig. 4 – Superior rectal artery embolization using microcoil (2 mm x 2 cm).**

## Discussion

The crucial step in the MIPH is the stapler excision of the anal columns above the dentate line, resulting in repositioning of the hemorrhoids into a more proximal site. This involves a purse string that invaginates the wall of the anorectum into the shaft of the stapler.<sup>2</sup> If the stapler head is larger, a correspondingly larger portion of the wall is included, and this would result in perirectal tissues being within the firing stapling position.<sup>3,4</sup> The superior haemorrhoidal artery runs very close to the wall of the rectum, and inclusion of a part of its wall would cause a pseudo aneurysm, which did not respond



**Fig. 5 – Stapler.**


to conventional oversewing of staple line. Angio embolization is the final port of call for a bleeding pseudo aneurysm, and this proved effective. Pseudoaneurysms arise from a disruption in arterial wall, with blood dissecting into the tissues around the damaged artery creating a perfused sac that communicates with the arterial lumen. They may be traumatic, iatrogenic (from surgical, endoscopic or radiological interventional procedures).<sup>4,5</sup>

When examined later, the Chinese stapler gun had an external diameter of 34.5 mm (Figs. 5 and 6), vis-a-vis the 33 mm of the standard guns. This could have resulted in inclusion of the wall of the vessel, and caused the pseudo aneurysm. It has been reported that if the size of stapler is more than 33 mm, the complication of bleeding is higher.<sup>1</sup>

Factors that may help to minimize the risk of bleeding: manual overstitching of the staple line; use of the 33 mm gun, which has a smaller staple closure and is more hemostatic; tightening the gun to the absolute limit; and use of a post-operative endoanal sponge. The bleeding rate decreased from 12.9% to 4.4% with the increasing experience of the performing surgeon.<sup>1,6,7</sup>

Only in one case have we encountered pseudo aneurysm, in a series of 28 MIPH cases done with the Chinese stapler guns. Although these are still very popular in India, in our unit we have given up the low cost stapler for MIPH.

Pseudo aneurysm of the superior rectal artery has been reported,<sup>5</sup> Pseudo aneurysm of the cystic artery or right hepatic artery after cholecystectomy and inadvertent lateral wall injury to the vessel, is well documented.<sup>2,8</sup> So is splenic artery or left gastric arterial pseudo aneurysm secondary to pancreatic pseudocyst or pancreatic necrosis. But to our



**Fig. 6 – View of the circumference of the stapler.**

knowledge, there are only few reported till now, on superior haemorrhoidal pseudo aneurysm, a rare complication of MIPH.

---

### Conclusion

This case report, of post MIPH pseudo aneurysmal bleeding, is being published as it is uncommon, and to highlight technical considerations in choice of stapler, etc., to avoid rare but deadly complications of an otherwise simple procedure.

---

### Conflicts of interest

The authors declare no conflicts of interest.

### REFERENCES

- 
1. Pescatori M, Gagliardi G. Postoperative complications after procedure for prolapsed hemorrhoids (PPH) and stapled transanal rectal resection (STARR) procedures. *Tech Coloproctol.* 2008.
  2. Ravo B, Amato A, Bianco V, Boccasanta P, Bottini C, Carriero A, et al. Complications after stapled hemorrhoidectomy: can they be prevented? *Tech Coloproctol.* 2002.
  3. Ho YH, Seow-Choen F, Tsang C, Eu KW. Randomized trial assessing anal sphincter injuries after stapled haemorrhoidectomy. *Br J Surg.* 2001;88:1449–55.
  4. Oughriss M, Yver R, Faucheron JL. Complications of stapled hemorrhoidectomy: a French multicentric study. *Gastroenterol Clin Biol.* 2005;29:429–33.
  5. Janmohamed A, Noronha L, Saini A, Elton C. An unusual cause of lower gastrointestinal haemorrhage. *BMJ Case Rep.* 2011.
  6. Angelone G, Giardiello C, Prota C. Stapled hemorrhoidopexy. Complications and 2-year follow-up. *Chir Ital.* 2006;58:753–60.
  7. Tebala GD, Khan AQ, Keane S. Major pelvic bleeding following a stapled transanal rectal resection: use of laparoscopy as a diagnostic tool. *Ann Coloproctol.* 2016;32:195–8.
  8. Fondran JC, Porter JA, Slezak FA. Inflammatory polyps: a cause of late bleeding in stapled hemorrhoidectomy. *Dis Colon Rectum.* 2006;49:1910–3.