



Journal of Coloproctology

www.jcol.org.br



Case Report

Mucocele of the vermiform appendix: diagnostic challenges and therapeutic approach

Carlos Magno Queiroz da Cunha^{a,*}, Douglas Marques Ferreira de Lima^a,
Giovanni Troiani Neto^a, Francisco Fernando Pimenta Lima^b,
Caio Regis de Oliveira Medeiros Pimenta^b, José Walter Feitosa Gomes^b

^a Universidade de Fortaleza, Curso de Medicina, Fortaleza, CE, Brazil

^b Hospital Gastroclinica, Serviço de Cirurgia, Fortaleza, CE, Brazil

ARTICLE INFO

Article history:

Received 21 August 2018

Accepted 26 November 2018

Available online 24 December 2018

Keywords:

Mucocele

Laparoscopy

Diagnosis, differential

ABSTRACT

Introduction: Mucocele of the appendix is defined as the obstructive dilatation of the vermiform appendix by the abnormal accumulation of mucinous substance in its lumen. Imaging tests may be useful, but they commonly fail to evidence the etiology in question. Regarding the therapeutic approach, there are different options for treatment. Appendectomy was routinely used in simple cystadenomas, with good results. However, in cases of neoplasias, more aggressive resection is necessary, and the therapeutic course of choice is the right hemicolectomy.

Case report: Patient presented to the surgery outpatient clinic with magnetic resonance imaging presenting an adnexal cyst of about 11.0 × 4.5 cm on the right. The patient had pain in the right iliac fossa for 6 months. Due to the radiological finding and persistence of the clinical picture, videolaparoscopy was performed, and an appendicular mass suggestive of mucocele was identified. A laparoscopic appendectomy was performed, with no signs of mucus extravasation. Histopathological analysis confirmed the diagnosis.

Discussion: Mucocele is rarely diagnosed effectively in the preoperatively. In this context, imaging tests do rarely evidence such etiology. Given the importance of preoperative diagnosis for the definition of conduct, it is essential that this condition be always taken into account as a diagnostic hypothesis.

© 2018 Sociedade Brasileira de Coloproctologia. Published by Elsevier Editora Ltda. This is an open access article under the CC BY-NC-ND license (<http://creativecommons.org/licenses/by-nc-nd/4.0/>).

* Corresponding author.

E-mail: carlosmagnoc@gmail.com (C.M. Cunha).

<https://doi.org/10.1016/j.jcol.2018.11.006>

2237-9363/© 2018 Sociedade Brasileira de Coloproctologia. Published by Elsevier Editora Ltda. This is an open access article under the CC BY-NC-ND license (<http://creativecommons.org/licenses/by-nc-nd/4.0/>).

Mucocele de apêndice vermiforme: desafios no diagnóstico e sua abordagem terapêutica

R E S U M O

Palavras-chave:

Mucocele
Laparoscopia
Diagnóstico diferencial

Introdução: A mucocele do apêndice é definida como a dilatação obstrutiva do apêndice vermiforme pelo acúmulo anormal de substância mucinosa em seu lúmen. Os exames de imagem podem ser úteis, porém não raramente falham em evidenciar a etiologia em questão. Em relação à abordagem terapêutica, existem diferentes opções de conduta. A apendicectomia foi o tratamento rotineiramente utilizado em cistoadenomas simples, com bons resultados. Todavia, em casos de neoplasias, é necessária ressecção mais agressiva, sendo a conduta terapêutica a hemicolectomia direita.

Relato de caso: Paciente compareceu ao ambulatório de cirurgia com ressonância magnética apresentando cisto anexial de cerca de 11,0 × 4,5 cm à direita. Apresentava quadro de dor em fossa ilíaca direita há 6 meses. Devido ao achado radiológico e persistência do quadro clínico foi realizado videolaparoscopia, sendo identificada massa apendicular sugestiva de mucocele. Foi realizada apendicectomia videolaparoscópica, sem extravasamento do conteúdo mucinoso. A análise histopatológica confirmou o diagnóstico.

Discussão: A mucocele raramente é diagnosticada de maneira eficaz no pré-operatório. Neste contexto, os exames de imagem não raramente falham em evidenciar tal etiologia. Diante da importância do diagnóstico pré-operatório para a definição da conduta, é essencial que sempre se leve em conta tal afecção como uma hipótese diagnóstica.

© 2018 Sociedade Brasileira de Coloproctologia. Publicado por Elsevier Editora Ltda. Este é um artigo Open Access sob uma licença CC BY-NC-ND (<http://creativecommons.org/licenses/by-nc-nd/4.0/>).

Introduction

Mucocele of the appendix is defined as the obstructive dilatation of the vermiform appendix, caused by abnormal production and accumulation of mucinous substance in its lumen, due to the alterations in the mucous and muscular layers.¹ It is a rare condition, observed in up to 0.4% of patients who undergo appendectomy, being more prevalent in women between the fifth and sixth decades of life.^{1,2} Its presentation can range from benign forms, such as simple mucocele and mucinous cystadenoma, to malignant conditions of worse prognosis, such as mucinous cystadenocarcinoma.^{2,3}

In the context of clinical symptomatology, the most common manifestation of mucocele of the appendix is abdominal pain, especially in the lower right quadrant, which presents with variable intensity and duration.^{2,3} The presence of a palpable mass in the right iliac fossa, weight loss, and other less usual symptoms in a general appendicitis situation may also be observed.³ Although most cases are asymptomatic or oligosymptomatic, some studies demonstrate a correlation between a more exuberant symptomatology and a greater histological degree of dysplasia.^{4–6}

While its morphology may be characteristic in imaging tests such as computed tomography, ultrasound, colonoscopy, and magnetic resonance imaging (MRI), diagnostic tools may be useful. This characteristic morphology is observed in only 40% of cases in the preoperative period, which leads to several radiological differential diagnoses such as acute appendicitis, malignant neoplasias, ovary cyst, mesenteric cyst, lymphocele, and inflammatory diseases, whose presentation mimics and can be confused with those characteristic of mucocele of

the appendix.^{5–7} In approximately 60% of the cases, the diagnosis is given only in the intraoperative period, usually during laparotomies that are indicated due to a suspicion of other etiologies, or as an occasional finding; the hypothesis is confirmed only after the result of histopathological analysis of the surgical specimen.^{7,8}

Regarding the therapeutic approach of the pathology, different options of management are available for different clinical presentations. Conventional appendectomy was the treatment routinely used in simple cystadenomas, with good results. However, in cases of neoplasias, a more aggressive resection of the affected area is necessary. In this context, the most appropriate therapeutic course is a right hemicolectomy following oncological principles. It is important to emphasize that, when defining surgical treatment, it is always important to analyze the clinical context of the patient, singularly considering their characteristics, clinical presentation, and comorbidities, in order to reach a therapeutic proposal consistent with their situation.^{8–10}

In view of the relevance and diagnostic difficulty of the mucocele of the appendix, the authors report the case of a patient who underwent videolaparoscopy, where the initial clinical and radiological suspicion was of a giant ovarian cyst, and the hypothesis of mucocele of the appendix was raised in the intraoperative period.

Case report

A 72-year-old woman, hypertensive, G2P2A0, presented to the surgical outpatient clinic with an MRI showing an adnexal cyst of about 11.0 × 4.5 cm to the right, without features suggestive

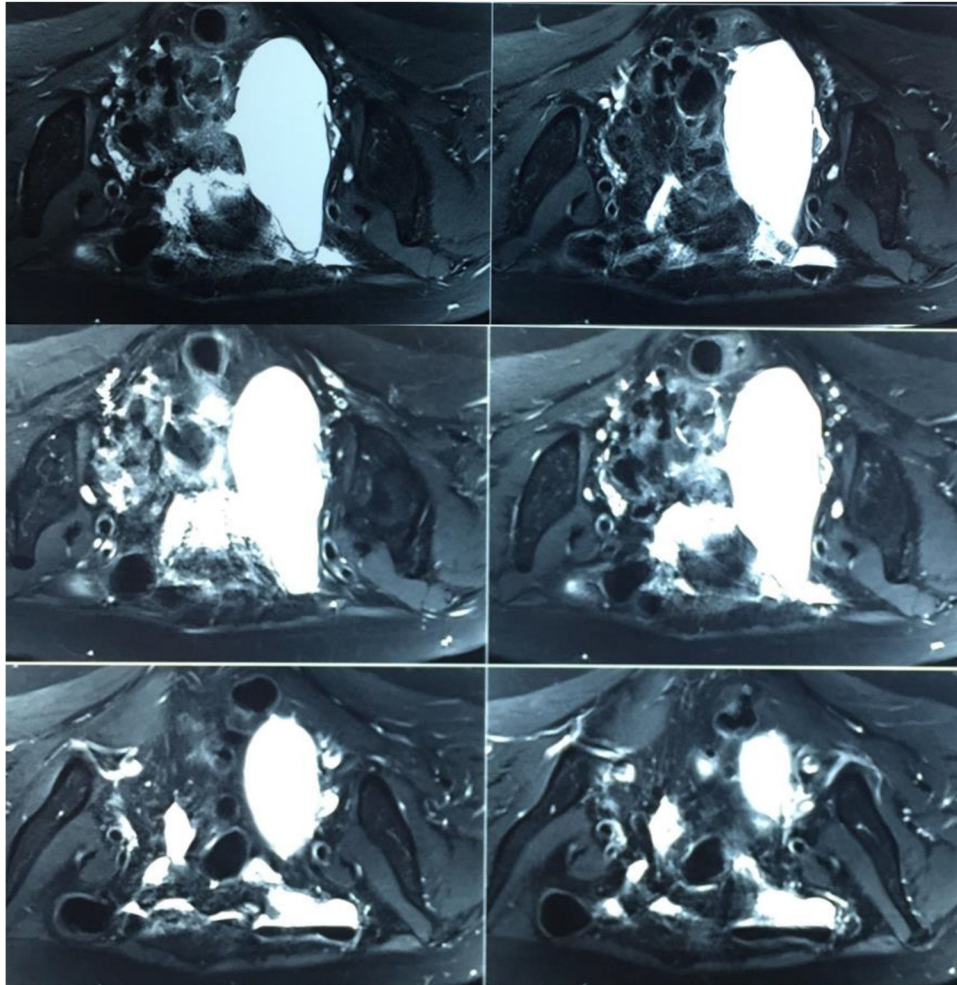


Fig. 1 – Magnetic resonance imaging showing adnexal cyst of about 11.0 × 4.5 cm on the right, with no characteristics suggestive of malignancy.

of malignancy (Fig. 1). The examination was indicated by a general practitioner due to intermittent abdominal pain in the right lower quadrant, which appeared about six months after the patient had sought treatment for the first time, without nausea, vomiting, postprandial fullness, genitourinary diseases, or any alterations in intestinal habits. The patient had a surgical history of abdominal hysterectomy approximately five years prior, due to uterine myomatosis, denying transvaginal bleeding, discharge, or any gynecological complaints since then. The patient denied having a history of neoplasias or other comorbidities.

Due to the radiological findings, and combined with the persistence of the clinical picture, which was detrimental to the patient's daily life, according to her own report, the authors opted to perform an elective videolaparoscopy; the necessary preoperative exams were requested and did not present alterations.

Despite the hypothesis raised after the findings of the imaging studies, an appendicular mass suggestive of mucocele was identified during videolaparoscopy (Fig. 2), without any adnexal or other findings. Laparoscopic appendectomy was performed, without extravasation of the mucinous contents,

with the aid of a latex bag. Post-operatively, the patient evolved well, without any complications, and was discharged after 24 h. The histopathological analysis of the surgical specimen confirmed the diagnostic hypothesis raised by assessing the macroscopic aspect: grade 1 mucocele of the appendix. At the post-operative outpatient follow-up consultations, two tumor markers (CEA and CA 50) were assessed and found to be within the normal limits.

Discussion

Mucocele of the appendix has a very variable clinical presentation and may even be asymptomatic. Symptoms, when present, are usually acute or chronic pain in the lower right quadrant, presence of palpable mass in the same quadrant, anemia, hematochezia, and alterations in intestinal transit, among other nonspecific symptoms. Therefore, while a preoperative diagnosis is very important to define the proper conduct, it is rarely done.¹⁻³

Despite the advances in imaging techniques, mainly ultrasound, computerized tomography, and MRI, the findings in

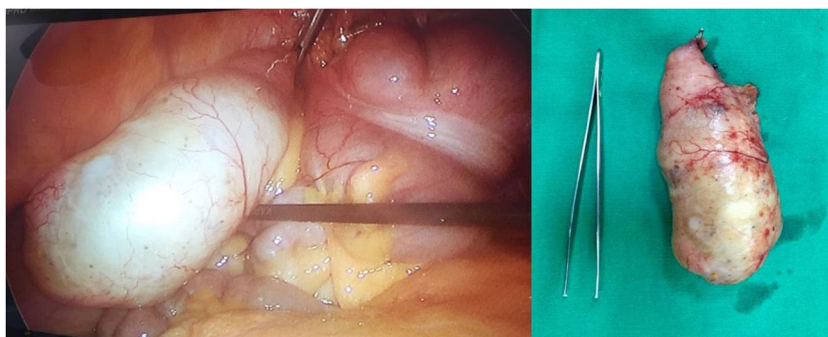


Fig. 2 – Intraoperative finding (left) and sample sent for anatomopathological study (right).

these exams are not always indicative of mucocele of the appendix. On ultrasound, the main finding would be the presence of a cystic mass of variable internal echogenicity. On computed tomography, the main finding would be the presence of an encapsulated abdominal mass, with regular and smooth walls, that would be observed in the lower right quadrant. Thus, differentiation between mucocele of the appendix and an uncomplicated appendicitis or an ovarian tumor is difficult.⁷

The previous diagnosis of this pathology is of great importance to define the adequate management; it allows a better planning of treatment and surgical approach, as an inadequate manipulation during the operative act can lead to the extravasation of mucin into the peritoneal cavity, harming the patient.^{8,9}

However, it is important to note that videolaparoscopic appendectomy is an acceptable treatment in cases of benign lesions. Thus, the different approaches to the pathology in question should be weighed, since patients who can safely undergo a videolaparoscopic can be widely benefited, as this procedure is a surgery that leads to less tissue aggression, stress, and metabolic response and, consequently, lower morbidity and mortality, complications, and length of hospital stay. Therefore, the individual characteristics of patients, such as age, epidemiological profile, and comorbidities should always be taken into consideration when choosing the surgical technique.^{9,10} In the case reported, due to the patient's age and comorbidities, a videolaparoscopic appendectomy was the technique of choice.

Another important consideration is the dosage of markers such as CEA and CA 50, both preoperatively and postoperatively, to identify possible colon or ovary malignancy.^{8,9} In the present case, such conduct was partially impaired, as the diagnosis was changed only intraoperatively. However, as already mentioned, these markers were promptly assessed postoperatively, and no greater damage was observed at follow-up.

Therefore, mucocele of the appendix is a rare condition with a variable clinical presentation that is rarely effectively diagnosed preoperatively, even when advanced complementary methods are used.⁴⁻⁶ In this context, although imaging exams may aid in diagnosis, they often fail to evidence or at least raise suspicion about such etiology.⁷ Given the significant importance of preoperative diagnosis in the definition of adequate management, it is essential that this condition

is always taken into account in the differential diagnosis, in order to increase the suspicion index when assessing these patients and thus reduce delays in diagnosis and, therefore, in treatment.^{7,8} Furthermore, mucocele of the appendix should be considered as a possible diagnosis whenever imaging tests demonstrate a mass in the lower right quadrant of a nonspecific character; surgical planning should include the possibility of this pathology, and treatment should be appropriate to the specific conditions of each patient.^{8,9}

Conflicts of interest

The authors declare no conflicts of interest.

REFERENCES

1. Yamane YD, Yamane H, Castro Júnior PC, Marsilac A, Mesquita RB, Paulo FL. Mucocele do apêndice - relato de caso e revisão da literatura. *Rev Bras Coloproct.* 2005;25:256-60.
2. Fonseca LM, Sassine GC, Luz MM, Silva RG, Conceição SA, Lacerda-Filho A. Cistoadenoma de apêndice: relato de caso e revisão da literatura sobre tumores mucinosos do apêndice vermiforme. *Rev Bras Coloproct.* 2008;28:89-94.
3. Guimarães Filho A, Magalhães JP, Campos ES, Guimarães JF, Alves JL Jr. Mucocele do apêndice. *Rev Col Bras Cir.* 2018;35:64-5.
4. Costa RGF. Mucocele de apêndice. *Rev Col Bras Cir.* 2009;36:180-2.
5. Polotto PPLS, Garcia MT, Gazola NF, Cretelli OS, Borim AA, Campos Junior E. Mucocele de apêndice vermiforme em paciente com câncer gástrico. *Arq Ciênc Saúde.* 2014;21:66-70.
6. Pando CS, Avila DS, Beier MM, Zagoury AR. Cistoadenoma mucinoso de apêndice em mulher idosa. *Rev AMRIGS.* 2010;54:63-6.
7. Madwed D, Mindelzun R, Jeffrey RB Jr. Mucocele of the appendix: imaging findings. *AJR Am J Roentgenol.* 1992;159:69-72.
8. Stocchi L, Wolff BG, Larson DR, Harrington JR. Surgical treatment of appendiceal mucocele. *Arch Surg.* 2003;138:585-9.
9. Lorenzon L, De Dominicis C, Virgilio E, Balducci G. The appropriate management of an appendiceal mucocele. *BMJ Case Rep.* 2015:2015, <http://dx.doi.org/10.1136/bcr-2014-209045>.
10. Singh MK, Kumar MK, Singh R. Laparoscopic appendectomy for mucocele of the appendix. *J Nat Sci Biol Med.* 2014;5:204-6.