




## Review Article

# Is total mesocolon excision necessary? A systematic review

Carlos Ramon Silveira Mendes  [a,b,c,d](#)

<sup>a</sup> Hospital Córdio Pulmonar, Serviço Coloproctologia, Salvador, BA, Brazil

<sup>b</sup> Hospital Santa Izabel-Santa Casa da Bahia, Salvador, BA, Brazil

<sup>c</sup> Hospital Geral Roberto Santos, Residência de Coloproctologia, Salvador, BA, Brazil

<sup>d</sup> Universidade de São Paulo (USP), Faculdade de Medicina, São Paulo, SP, Brazil

### ARTICLE INFO

#### Article history:

Received 7 January 2019

Accepted 21 April 2019

Available online 25 May 2019

#### Keywords:

Morbidity

Mortality Videolaparoscopy

#### Palavras-chave:

Morbidade

Mortalidade

Videolaparoscopia

### ABSTRACT

Complete mesocolon excision is an alternative in the treatment of neoplasias. The open technique was initially described for the procedure; however, it has some limitations. In this scenario, videolaparoscopic surgery is a minimally invasive alternative; however, its use in complete mesocolon excision is controversial. This study aimed to evaluate the results of videolaparoscopic complete mesocolon excision. A systematic review of the literature was performed for this study. Nine articles were selected, comprising 860 patients. The surgical results demonstrate the quality of the videolaparoscopic technique, which presents low morbidity and mortality and high survival rates after five years. Videolaparoscopy is a safe and effective method for complete mesocolon excision.

© 2019 Published by Elsevier Editora Ltda. on behalf of Sociedade Brasileira de Coloproctologia. This is an open access article under the CC BY-NC-ND license (<http://creativecommons.org/licenses/by-nc-nd/4.0/>).

### Excisão total do mesocolon é necessário? Uma revisão sistemática

#### RESUMO

A excisão completa do mesocolon constitui-se como alternativa para o tratamento de neoplasias. A técnica aberta foi descrita inicialmente para a realização do procedimento, no entanto apresenta algumas limitações. Nesse cenário a cirurgia por videolaparoscopia apresenta-se como alternativa minimamente invasiva, no entanto sua empregabilidade para a excisão completa do mesocolon é motivo de controvérsia. O objetivo deste trabalho é estudar os resultados oriundos da cirurgia por videolaparoscopia aplicada à excisão completa do mesocolon. A revisão sistemática da literatura foi utilizada para a realização deste estudo. Nove artigos científicos foram selecionados, compreendendo 860 pacientes. Os resultados cirúrgicos demonstram a qualidade da técnica por videolaparoscopia, que

E-mail: [proctoramom@hotmail.com](mailto:proctoramom@hotmail.com)

<https://doi.org/10.1016/j.jcol.2019.04.002>

2237-9363/© 2019 Published by Elsevier Editora Ltda. on behalf of Sociedade Brasileira de Coloproctologia. This is an open access article under the CC BY-NC-ND license (<http://creativecommons.org/licenses/by-nc-nd/4.0/>).

apresenta baixa morbidade e mortalidade e com altas taxas de sobrevivência após cinco anos. A videolaparoscopia aplicada à excisão completa do mesocolon apresenta qualidade que possibilita a realização da excisão completa do mesocolon de forma segura e eficaz.

© 2019 Publicado por Elsevier Editora Ltda. em nome de Sociedade Brasileira de Coloproctologia. Este é um artigo Open Access sob uma licença CC BY-NC-ND (<http://creativecommons.org/licenses/by-nc-nd/4.0/>).

---

## Introduction

Minimally invasive surgery techniques, such as videolaparoscopy, allow surgical procedures to be performed through minimally invasive incisions, contributing to the reduction of postoperative pain, lower infection rates, and earlier recovery when compared with other methods.

Mesocolic excision can be used in the treatment of colon cancer, aiming to remove the colonic tissue affected by neoplasia as well as accessory tissues. The technique can be performed through open surgery, from the lateral-medial approach, or through laparoscopic surgery, in which an incision along the mesenteric axis, near the superior mesenteric vein is performed from medial-to-lateral or down-to-up approaches.

The scientific evidence about the use of laparoscopic technique for complete excision resides in retrospective studies; furthermore, in these studies, the patient follow-up periods were insufficient to evaluate surgical outcomes such as cancer recurrence or even whether interindividual differences, such as body mass index, may affect the surgical outcome.

In addition, it is estimated that the laparoscopic technique is associated with a 16% increase in the risk of death, as well as an 11% increase in the risk of cancer recurrence.<sup>1</sup> In turn, technological developments have allowed better results in laparoscopic surgeries, minimizing the risk of recurrence and mortality.<sup>2,3</sup>

Therefore, this study aimed to assess the surgical results of laparoscopic total mesocolon excision, by analyzing prospective studies that described the surgical results and the period of follow-up of these patients.

---

## Methods

This was a systematic review, elaborated according to the Preferred Reporting Items for Systematic Reviews and Meta-Analyses (PRISMA) guidelines.<sup>3</sup> The Patients, Intervention, Comparison, and Outcome (PICO) strategy was adopted for article selection: (1) Patients: patients who underwent surgery for total mesocolon excision; (2) Intervention: videolaparoscopic surgery; (3) Comparison: analysis of the results obtained and (4) Outcome: association between video technique and levels of morbidity and mortality.

### Search strategy

In October 2018, a search was conducted in the PubMed and Cochrane Library databases, restricted to content published between the years 2005 and 2018 in the English language.

The following search strategy was adopted: “Total Mesocolon Excision” OR “Complete Mesocolon Excision” AND “Videolaparoscopy”.

In addition to the systematic search, studies were retrieved based on the bibliographic reference of related studies.

### Inclusion and exclusion criteria

The inclusion criteria comprised clinical studies describing the use of videolaparoscopic technique for total mesocolon excision.

Studies in animals or *in vitro* models, published in a language other than English, and case reports or letters to the editor were not included in this study.

### Method of selection and data extraction

Duplicate articles and those who did not match the search topic were excluded from the search result. The abstracts of the remaining systematic review or meta-analysis articles were evaluated, and articles were selected in accordance with the inclusion criteria.

Data extraction comprised the following data: author, year of publication, sample and age, body mass index, intraoperative complications, postoperative complications, and length of hospital stay.

### Evaluation of methodological quality

The level of evidence of the selected studies was evaluated in accordance with the scale provided by the Centre for Evidence-based Medicine, Oxford, UK. The studies were classified into five levels, according to the level of evidence for the study problem (Fig. 1).<sup>4</sup>

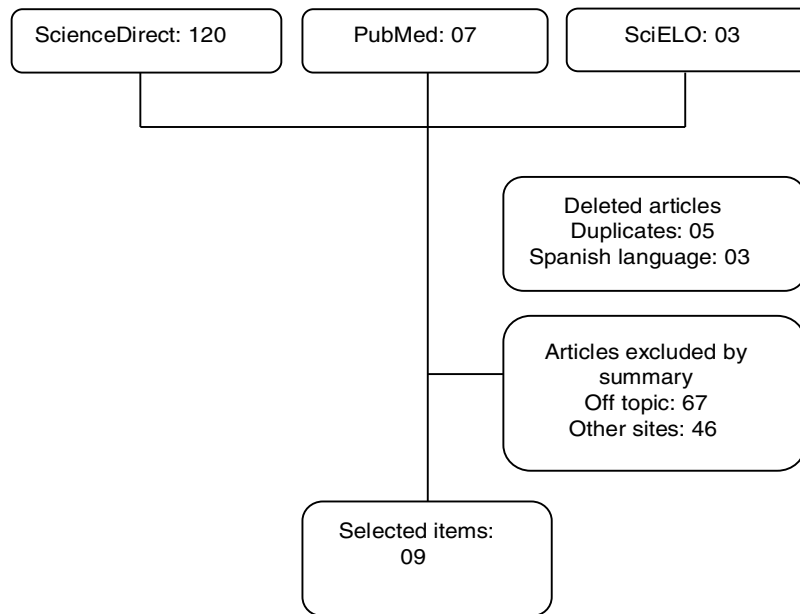
---

## Results

A total of 120 citations were retrieved through the search mechanism, among which nine met the inclusion criteria, totalling 860 patients who underwent videolaparoscopic procedure under different surgical conditions.

In accordance with the Oxford quality score,<sup>4,5</sup> the methodological quality of the studies was considered poor. However, the double-blinded methodology is one of the main characteristics of the Oxford scale; prospective studies do not present such characteristics, resulting in low scores on the Oxford scale.

Nevertheless, patients were followed-up for a mean of 24 months, a variable that is not included in the Oxford scale and



**Fig. 1 – Study design.**

**Table 1 – Selected articles.**

Author, year	Sample/age/BMI	Surgical time (min)	Complications	Length of hospital stay
Adamina et al., 2012 <sup>8</sup>	52/75 years/27.3 kg/m <sup>2</sup>	136	5 (0.9%)	3 days
Takemasa et al., 2013 <sup>9</sup>	150/65.6 years/22.4 kg/m <sup>2</sup>	173	25(16.7)	8.7 days
Kang et al., 2014 <sup>10</sup>	128/66 years/23.5 kg/m <sup>2</sup>	192	12 (9%)	5 days
Huang et al., 2015 <sup>11</sup>	53/56 years/NA	194	2 (0.3%)	11 days
Kim et al., 2016 <sup>12</sup>	116/67 years/23.5 kg/m <sup>2</sup>	175	30 (25%)	11 days
Mori et al., 2017 <sup>13</sup>	24/72.1 years/NA	274	3 (12.5%)	15 days
Wang et al., 2017 <sup>14</sup>	172/67 years/NA	113.5	28 (16%)	
Spinoglio et al., 2018 <sup>15</sup>	101/71.2 years/25.1 kg/m <sup>2</sup>	236	28 (27.7%)	7.9 days
Mori et al., 2018 <sup>16</sup>	65/67.6 years/22.8 kg/m <sup>2</sup>	283	6 (10%)	NA

that contributes to the methodological quality of the selected studies.

Total mesocolon excision aims to remove the tissue affected by neoplasias, while simultaneously removing the surrounding lymph nodes. Laparoscopic surgery is still controversial, and some centers have used open surgery for the removal of tumors and other treatments.<sup>5</sup>

Total mesocolon removal was initially described through open surgery; however, the videolaparoscopic procedure was described as safe in a large number of studies.<sup>7</sup>

The results selected in Table 1 indicate that total colon excision performed through videolaparoscopy on the right side presented a shorter operation time (green dots; Table 1). Takemasa et al. (2014)<sup>9</sup> reported having performed laparoscopic procedures on both sides, however, the authors indicated that surgeries performed on the right side had shorter execution times.

Huang et al. (2015) compared the results between open and laparoscopic surgery for total mesocolon excision and observed shorter operating time for open surgery (mean: 117 min.); however, patients who underwent this approach

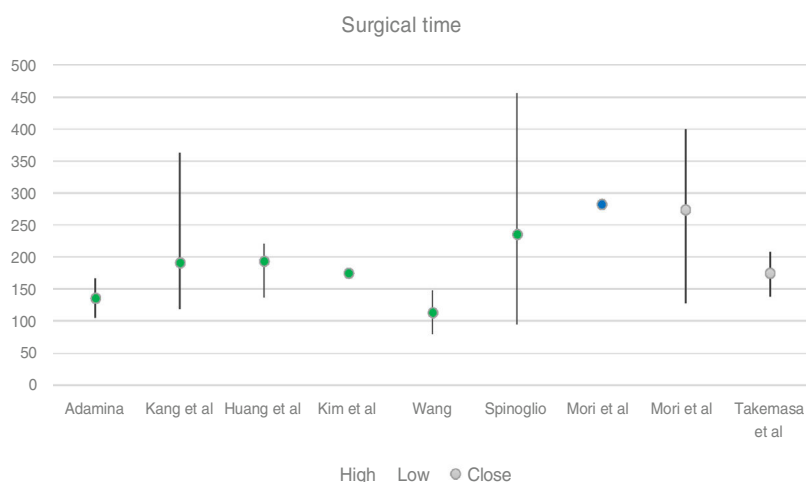
presented greater blood loss, longer incision length, and longer hospital stay.<sup>11</sup>

Surgical duration is related to the experience of the surgeon and the degree of impairment of the affected tissue. Scientific evidence indicate that the laparoscopic procedure lasts 180–260 min, a finding that is in agreement with the results observed in the present review (Fig. 2).<sup>17</sup>

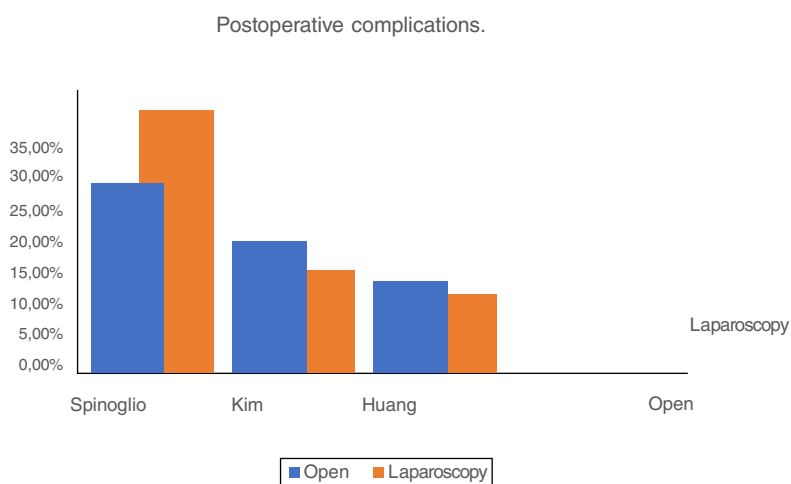
Despite the longer operating time when compared with open surgery, laparoscopic surgery presents fewer complications and infections.

Conversion to open surgery (Fig. 3) has the potential to increase the incidence of complications in anastomoses by approximately 29%.<sup>18</sup> Among the studies analyzed, Kim et al.<sup>12</sup> reported the highest conversion ratio for open surgery. According to Shawki et al., any additional incision performed earlier than planned can be considered conversion to open surgery, which could influence the surgical results.<sup>19</sup>

The survival time reached rates of 73% in five years,<sup>15</sup> while cancer recurrence was not reported in the studies analyzed. The data presented are in agreement with those of a



**Fig. 2 – Surgical time among selected studies.**



**Fig. 3 – Postoperative complications.**

controlled clinical study in which the survival rate reached 74.2% for laparoscopic surgery, compared to 76.2% for open surgery.<sup>20,21,22,23,24</sup>

**Conclusion**

Total mesocolon excision surgery is reproducible; compatible results were observed regardless of the center in which the studies were performed. When compared to open surgery, the videolaparoscopic technique presented superior postoperative morbidity and mortality results.

The videolaparoscopy technique has some limitations, including the high cost of the equipment required to perform the technique; it also requires extensive surgeon experience, which is directly reflected in the operation time as well as possible conversion to open surgery.

The present study demonstrated the quality of the videolaparoscopic technique for total mesocolon excision, with

comparable or superior results than the open technique, providing excellent results with minimally invasive practices.

**Conflicts of interest**

The author declares no conflicts of interest.

**REFERENCES**

1. Dalibon N, Moutafis M, Fischler M. Laparoscopically assisted versus open colectomy for colon cancer. *N Eng J Med.* 2004;351:933-4.
2. Gopall J, Shen X, Cheng Y. Current status of laparoscopic total mesorectal excision. *Am J Surg.* 2012;203:230-41.
3. Liberati A, Altman DG, Tetzlaff J, Mulrow C, Gotzsche PC, Loannidis JP, et al. The PRISMA statement for reporting systematic reviews and meta-analysis of studies that

- evaluate health care interventions: explanations and elaboration. *PLOS Med.* 2009;6:e1000100.
4. OCEBM. The Oxford levels of evidence 2. OCEBM Levels of Evidence Working Group Oxford; 2011. Available from: <https://www.cebm.net/index.aspx?o=5653> [accessed 05.09.18].
  5. Jadad AR, Moore RA, Carroll D, Jenkinson C, Reynolds DJ, Gavaghan DJ, et al. Assessing the quality of reports of randomized clinical trials: is blinding necessary? *Control Clin Trials.* 1996;17:1–12.
  6. Chow C, Kim S. Laparoscopic complete mesocolic excision: west meets east. *World J Gastroenterol.* 2014;20:14301–7.
  7. Bertelsen CA, Kirkegaard-Klitbo A, Nielsen M, Leotta SM, Daisuke F, Gögenur I. Pattern of colon cancer lymph node metastases in patients undergoing central mesocolic lymph node excision: a systematic review. *Dis Colon Rectum.* 2016;59:1209–21.
  8. Adamina M, Manwaring ML, Park KJ, Delaney CP. Laparoscopic complete mesocolic excision for right colon cancer. *Surg Endosc.* 2012;26:1976–80.
  9. Takemasa I, Uemura M, Nishimura J, Mizushima T, Yamamoto H, Ikeda M, et al. Feasibility of single-site laparoscopic colectomy with complete mesocolic excision for colon cancer: a prospective case-control comparison. *Surg Endosc.* 2014;28:1110–8.
  10. Kang J, Kim IK, Kang SI, Sohn SK, Lee KY. Laparoscopic right hemicolectomy with complete mesocolic excision. *Surg Endosc.* 2014;28:2747–51.
  11. Huang JL, Wei HB, Fang JF, Zheng ZH, Chen TF, Wei B, et al. comparison of laparoscopic versus open complete mesocolic excision for right colon cancer. *Int J Surg.* 2015;23:12–7.
  12. Kim IY, Kim BR, Choi EH, Kim YW. Short-term and oncologic outcomes of laparoscopic and open complete mesocolic excision and central ligation. *Int J Surg.* 2016;27:151–7.
  13. Mori S, Kita Y, Baba K, Yanagi M, Tanabe K, Uchikado Y, et al. Laparoscopic complete mesocolic excision via combined medial and cranial approaches for transverse colon cancer. *Surg Today.* 2017;47:643–9.
  14. Wang Y, Zhang C, Zhang D, Fu Z, Sun Y. Clinical outcome of laparoscopic complete mesocolic excision in the treatment of right colon cancer. *World J Surg Oncol.* 2017;15:1–6.
  15. Spinoglio G, Bianchi PP, Marano A, Priora F, Lenti LM, Ravazzoni F, et al. Robotic vs. laparoscopic right colectomy with complete mesocolic excision for the treatment of colon cancer: perioperative outcome and 5 year survival in a consecutive series of 202 patients. *Ann Surg Oncol.* 2018;25:3580–6.
  16. Mori S. Laparoscopic complete mesocolic excision via mesofacial separation for left-sided colon cancer. *Surgery Today.* 2018;48:274–81.
  17. Guillou PJ, Quirke P, Thorpe H, Walker J, Jayne DG, Smith AM, et al. Short-term endpoints of conventional versus laparoscopic-assisted surgery in patients with colorectal cancer (MRC CLASICC trial): multicentre, randomised controlled trial. *Lancet.* 2005;365:1718–26.
  18. Ströhlein MA, Grützner KU, Jauch KW, Heiss MM. Comparison of laparoscopic vs. open access surgery in patients with rectal cancer: a prospective analysis. *Dis Colon Rectum.* 2008;51:385–91.
  19. Shawki S, Bashankaev B, Denoya P, Seo C, Weiss EG, Wexner SD. What is the definition of “conversion” in laparoscopic colorectal surgery? *Surg Endosc.* 2009;23:2321–6.
  20. Colon Cancer Laparoscopic or Open Resection Study Group Buunen M, Veldkamp R, Hop WC, Kuhry E, Jeekel J, et al. Survival after laparoscopic surgery versus open surgery for colon cancer: long-term outcome of a randomised clinical trial. *Lancet Oncol.* 2009;10:44–52.
  21. Zheng M, Zhang S, Feng B. Complete mesocolic excision: lessons from anatomy translating to better oncologic outcome. *World J Gastrointest Oncol.* 2016;8:235–9.
  22. Zhou H, Ruan C, Sun Y, Zhang J, Wang Z, Hu Z. Nerve-guided laparoscopic total mesorectal excision for distal rectal cancer. *Ann Surg Oncol.* 2015;22:550–1.
  23. NIH National Heart, Lung, and blood institute. Study Quality Assessment Tools, 2018. Available from: <https://www.nhlbi.nih.gov/health-topics/study-quality-assessment-tools> [accessed 15.10.18].
  24. Agalianos C, Gouvas N, Dervenis C, Tsiaoussis J, Theodoropoulos G, Theodorou D, et al. Is complete mesocolic excision oncologically superior to conventional surgery for colon cancer? A retrospective comparative study. *Ann Gastroenterol.* 2017;30:688–96.