



Journal of Coloproctology


www.jcol.org.br



Case Report

Pneumatosis cystoides intestinalis – an incidental finding with unpredictable evolution



Marisa D. Santos ^{a,b,*}, Cláudio Silva^a, Ana Cristina Silva^{a,b}, Marta Salgado^{b,c},
Manuela França^{b,d}

^a Centro Hospitalar do Porto, Largo Professor Abel Salazar, Departamento de Cirurgia, Unidade Colorretal, Porto, Portugal

^b Universidade do Porto, Instituto de Ciências Biomédicas Abel Salazar, Porto, Portugal

^c Centro Hospitalar do Porto, Largo Professor Abel Salazar, Serviço de Gastroenterologia, Porto, Portugal

^d Centro Hospitalar do Porto, Serviço de Radiologia, Porto, Portugal

ARTICLE INFO

Article history:

Received 29 April 2019

Accepted 15 September 2019

Available online 27 October 2019

Keywords:

Pneumatosis cystoides intestinalis

Pneumoperitoneum

Bowel dilatation

Intestinal cysts

Extra-luminal gas

ABSTRACT

Pneumatosis cystoides intestinalis is an uncommon disease with unknown etiology characterized by the presence of multiple gas-filled cysts within the submucosa or subserosa of the intestinal wall. Pneumoperitoneum and/or intestinal perforation are complications that may be associated with pneumatosis cystoides intestinalis. The patients are often prone to misdiagnosis or mistreatment.

We are presenting a case of pneumatosis cystoides intestinalis in a 42 year-old woman affected by peritoneal free air and numerous, diffuse, bubble-like intramural gas collections into the jejunum and ileum, showed in CT-enterography images. The woman had a carcinoid tumor located in jejunum two years ago, treated with enterectomy. Recent complaints of nonspecific symptoms of abdominal discomfort and diarrhea motivated the realization of CT scan, serum chromogranin and urine 5-hidroxiindolacetic acid for hypothesis of tumor carcinoid recurrence withdraw. The only change found was the presence of pneumatosis cystoides intestinalis in CT-enterography images without intestinal necrosis, bleeding or evident obstruction. For that reason no surgical procedure was realized and the patient stayed on surveillance. Actually, the patient complaints are sporadic abdominal discomfort, without pneumatosis cystoides intestinalis clinical evidence.

Conclusion: The treatment plan of patient with PCI depends on underlying cause and clinical condition severity. When conservative treatment is adopted the clinical evolution of pneumatosis cystoides intestinalis is unpredictable and can even disappear in an indeterminate number of patients.

Published by Elsevier Editora Ltda. on behalf of Sociedade Brasileira de Coloproctologia.

This is an open access article under the CC BY-NC-ND license (<http://creativecommons.org/licenses/by-nc-nd/4.0/>).

* Corresponding author.

E-mail: marisasantos.cirurgia1@chporto.min-saude.pt (M.D. Santos).

<https://doi.org/10.1016/j.jcol.2019.09.005>

2237-9363/Published by Elsevier Editora Ltda. on behalf of Sociedade Brasileira de Coloproctologia. This is an open access article under the CC BY-NC-ND license (<http://creativecommons.org/licenses/by-nc-nd/4.0/>).

Pneumatose cistoide intestinal – um achado incidental com evolução imprevisível

R E S U M O

Palavras-chave:

Pneumatose cistoide intestinal
Pneumoperitoneu
Dilatação intestinal
Cistos intestinais
Gás extraluminal

A pneumatose cistoide intestinal é uma doença incomum, de etiologia desconhecida, caracterizada pela presença de múltiplos cistos preenchidos com gás na submucosa ou subserosa da parede intestinal. O pneumoperitoneu e/ou a perfuração intestinal são complicações que podem estar associadas à pneumatose cistoide intestinal. Os pacientes geralmente estão sujeitos a erros de diagnóstico ou de tratamento.

Apresentamos um caso de pneumatose cistoide intestinal em paciente do sexo feminino, 42 anos de idade, com ar livre peritoneal e numerosas coleções gasosas intramurais, difusas e semelhantes a bolhas no jejuno e íleo, visualizados em imagens de enterografia por tomografia computadorizada (TC). Há dois anos, a paciente teve um tumor carcinóide localizado no jejuno que foi tratado com enterectomia. As queixas recentes de sintomas inespecíficos, desconforto abdominal e diarreia motivaram a realização da TC e exame de cromogranina sérica e ácido 5-hidroxiindolacético na urina para excluir a hipótese de recorrência do tumor carcinóide. A única alteração encontrada foi a presença de pneumatose cistoide intestinal em imagens de enterografia por TC sem necrose intestinal, sangramento ou obstrução evidente. Por esse motivo, nenhum procedimento cirúrgico foi realizado, e a paciente permaneceu em observação. Atualmente, a queixa da paciente é de desconforto abdominal esporádico, sem evidência clínica de pneumatose cistoide intestinal.

Conclusão: O plano de tratamento de pacientes com PCI depende da causa subjacente e da gravidade da condição clínica. Quando o tratamento conservador é adotado, a evolução clínica da pneumatose cistoide intestinal é imprevisível e pode até desaparecer em alguns pacientes.

Publicado por Elsevier Editora Ltda. em nome de Sociedade Brasileira de Coloproctologia. Este é um artigo Open Access sob uma licença CC BY-NC-ND (<http://creativecommons.org/licenses/by-nc-nd/4.0/>).

Introduction

Pneumatosis cystoides intestinalis is a clinical entity and may be very heterogeneous representing a challenge for the clinician. It is characterized by polycystic air in the submucosa or subserosa of the intestine developing acute abdomen with intestinal obstruction, intestinal necrosis, perforation, pneumoperitoneum and/or peritonitis, or being present with nonspecific abdominal complaints.¹ The CT scan may confirm the diagnosis, give some additional information, providing differential diagnosis, to help determining the primary cause or some possible coexistent complications.² It usually related to respiratory infections, tumor or collagen disease, traumas, immunosuppression.³⁻⁵ Treatment plan to PCI patients depend on underlying cause, and clinical condition severity.

Case report

A 42 year-old woman with recent nonspecific symptoms of abdominal discomfort, nausea and diarrhea was observed in a routine surgical outpatient appointment. The patient was submitted to an enterectomy two years ago for a jejunum carcinoid tumor. The physical examination detected a median incision scar, and only a slight tenderness at palpation in the epigastrium with no acute abdomen. CT scan, serum chromogranin and urine 5-hidroxiindolacetic acid were performed to withdraw tumor carcinoid recurrence hypothesis. Patient

study was completed with complete blood count, blood biochemistry with amylase, lipase, creatinine phosphokinase, alkaline phosphatase and lactic dehydrogenase among others, and CT enterography. The only unexpected change found was the presence of PCI in CT enterography images with pneumoperitoneum but without intestinal necrosis, bleeding or evident obstruction. The CT enterography images showed the presence of numerous gas collections within the wall of the small bowel, consisting mainly of isolated bubbles, free intraperitoneal airs, multiple air-fluid levels, and distention in the small bowel, proximal to ileo-ileal anastomosis (Fig. 1).

A conservative approach with antibiotic therapy was adopted with patient symptoms improvement. She was medicated with proton pump inhibitor (omeprazole 20 mg/day), metoclopramide (10 mg 15 min before breakfast, lunch and dinner) during two months and antibiotic (rifaximin 200 mg 12/12 h during 12 days).

Actually, sporadic abdominal pain and discomfort, but without PCI, are the only patient complaints (study with CT enterography and capsule enteroscopy) (Fig. 2) or tumor recurrence.

Discussion

PCI is a rare condition characterized by multilocular gas-filled cysts localized in the submucosa and subserosa, most frequently observed in the terminal ileum of gas-trointestinal tract.⁶ The incidence of PCI is unknown and the etiology is

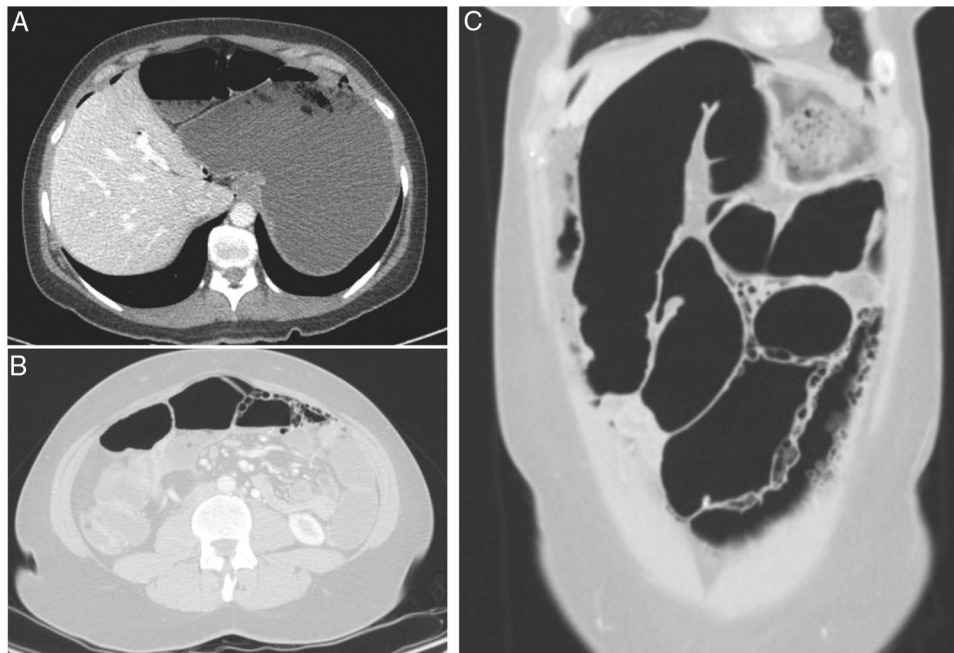


Fig. 1 – CT enterography (A, axial image; B and C, axial and coronal images, lung window) demonstrates free extra-peritoneal gas (arrows) and multiple air-filled cysts in the small bowel walls. There were no other abnormalities in the small bowel or in the colon.

unclear. Pneumatosis cystoides intestinalis can be classified as primary disease, (15%) of unknown cause, and secondary (85%) associated to gastrointestinal diseases, such as intestinal obstruction, cystic fibrosis, peptic ulcer, diverticula, inflammatory bowel disease, mesenteric infarction, chronic intestinal pseudo-obstruction, respiratory infections, tumor or collagen disease, traumas, immunosuppression and the use of steroids.⁷

The underlying diagnosis, when the cause is secondary, is not always easy.

There are several theories to explain the secondary PCI pathogenesis⁸: mechanical theory, bacterial theory, pulmonary theory, and chemical theory. The mechanical theory suggests existence of air inflow through damaged mucosa, caused by intestinal obstruction, severe constipation, gastrointestinal ulcers, or intestinal necrosis, resulting in increased intestinal pressure. The bacterial theory suggests the invasion of gas-producing bacteria into intestinal submucosa, producing gas at the intestinal walls. The pulmonary

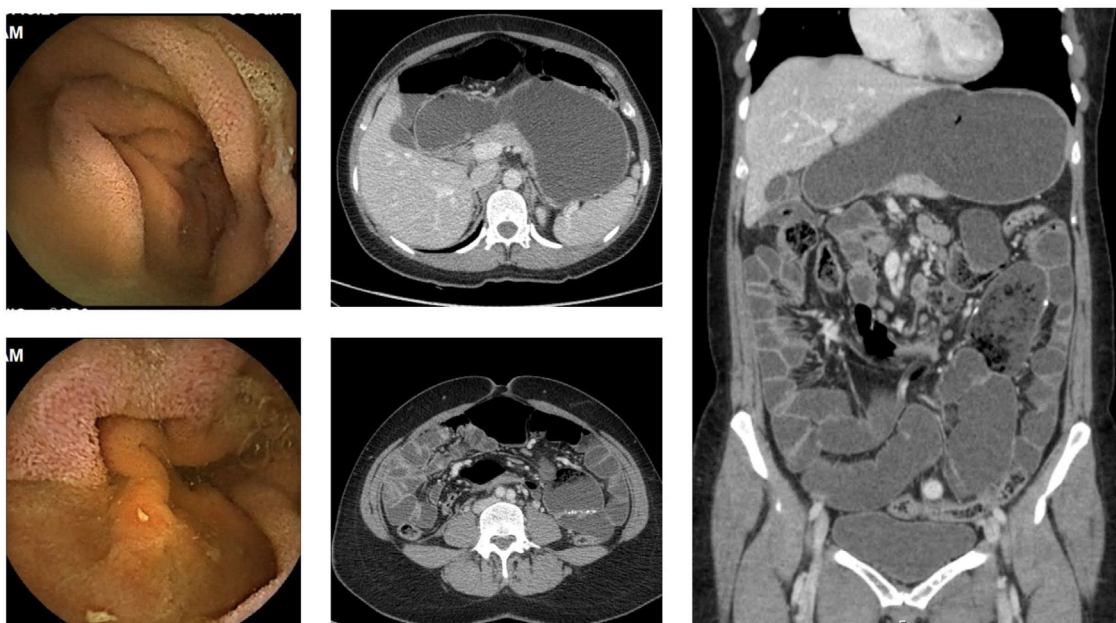

Fig. 2 – Capsule endoscopy and CT enterography images, 6 months after the acute event. Signs of pneumatosis are absent with few enteric stasis near the enteric anastomosis in CT enterography.

theory believes the existence of gas inflow into the peritoneal cavity, mesentery, and intestinal walls via mediastinum from damaged alveoli, due to increased intrathoracic pressure consequent from Chronic Obstructive Pulmonary Disease (COPD) or coughing. The chemical theory deems that the cause is occupational, related to continuous trichloroethylene exposure.⁹ The theories most accepted are bacterial and the decrease in the mucosa permeability.

In our patient, we believe that PCI developed secondary to post-operative gastrointestinal pseudo-obstruction, presumably stemmed from continuous dilatation and increased pressure due to some degree of obstruction provoked by previous surgery, with gas-producing bacteria growth in intestinal lumen. Our patient did not present a history of respiratory pathology or gastrointestinal complaints, namely constipation.

Regarding symptomatology, PCI is usually asymptomatic.¹⁰ PCI symptoms, if any, are usually secondary to an underlying disease. Spectrum of symptoms are wide, from nonspecific such as abdominal discomfort, diarrhea, constipation or weight loss; to severe complications, including intestinal obstruction, intestinal perforation, bleeding, pneumoretroperitoneum or peritonitis.

Plain radiographs, USG, CT, upper gastrointestinal endoscopy, and colonoscopy can be used for diagnosis. Radiological tools are important for diagnosing PCI surgical indication, and also to exclude intra-abdominal pathologies.²

So, treatment of PCI depends on the underlying cause and if PCI is symptomatic or not. Surgical exploration is required in acute abdomen and a conservative approach is defensible if the physical examination and imaging findings are not suspicious.¹¹ Conservative approaches, including nasogastric decompression, intestinal rest, antibiotic therapy and oxygen, are recommended for patients with positive examination findings and normal biochemical parameters, being confirmed radiologically to exclude intestinal ischemia or perforation.¹² On the other hand, an incidental finding of PCI is usually benign and does not require treatment.¹³ There is not a specific treatment for asymptomatic patients. The asymptomatic patients can be submitted to hyperbaric oxygen, and spontaneous remission can achieve rates of 50%.¹⁴ There are no guidelines about tests and how often they should be done, nor consensus about the therapeutics to adopt.

In our patient, the PCI findings were unexpected, and for this reason the attitude was no-surgical after screening possible recurrence of carcinoid tumor. In the last 6 months, we followed the clinical and imaging patient evolution. The patient has a sporadic abdominal discomfort but without PCI clinical evidence or tumor recurrence. Is our intention to keep a conservative approach, unless clinical symptoms get worse associated again with PCI imagiologic images. We intend to keep a six month surveillance, unless the patient present again symptoms. If so, the patient should be observed immediately at the Hospital.

Conclusion

Pneumatosis cystoides intestinalis refers to intramural gas often presenting as one incidental finding in benign cases.

Patients treatment with PCI, depend on underlying cause and clinical condition severity. Benign PCI should always be treated conservatively. When conservative treatment is adopted the clinical evolution of PCI is unpredictable and can even disappear in an indeterminate number of patients.

Conflicts of interest

The authors declare no conflicts of interest.

REFERENCES

- Ooi S, Das K, Toh JWT. Pneumatosis cystoides intestinalis: a benign differential diagnosis for computed tomographic evidence of pneumoperitoneum in a stable patient. *ANZ J Surg.* 2018;88:E210–1.
- Mavrogenis G, Chapeaux X, Benali V, Warzee P. Pneumatosis cystoides intestinalis: modern diagnostic modalities. *Dig Liver Dis.* 2013;45:617.
- Patel RV, Sutton PA, Colliver D, Stewart R. Pneumoperitoneum and pneumatosis cystoides intestinalis (PCI) following chemotherapy in an adolescent with Hodgkin's lymphoma. *BMJ Case Rep.* 2014;2014.
- Kaneko M, Sasaki S, Teruya S, Ozaki K, Ishimaru K, Terai E, et al. Pneumatosis cystoides intestinalis in patients with systemic sclerosis: a case report and review of 39 Japanese cases. *Case Rep Gastrointest Med.* 2016;2016:2474515.
- Gonzalez-Olivares C, Palomera-Rico A, Romera-Pintor Blanca N, Sánchez-Aldehuelo R, Figueroa-Tubío A, García de la Filia I, et al. Pneumatosis intestinalis in Crohn's disease. *Gastroenterol Hepatol.* 2019;42:181–3.
- Suarez V, Chesner IM, Price AB, Newman J. Pneumatosis cystoides intestinalis. Histological mucosal changes mimicking inflammatory bowel disease. *Arch Pathol Lab Med.* 1989;113:898–901.
- Devgun P, Hassan H. Pneumatosis cystoides intestinalis: a rare benign cause of pneumoperitoneum. *Case Rep Radiol.* 2013;2013:353245.
- Wada K, Takeuchi N, Emori M, Takada M, Nomura Y, Otsuka A. Two cases of pneumatosis cystoides intestinalis with intraperitoneal free air. *Gastroenterology Res.* 2017;10:208–11.
- Kumagai S, Ota H. A degreasing worker with pneumatosis cystoides intestinalis caused by trichloroethylene exposure. *Sangyo Eiseigaku Zasshi.* 2015;57:33–6.
- Ooi SM. Pneumoperitoneum in a non-acute abdomen-pneumatosis cystoides intestinalis. *Surg Case Rep.* 2015;1:44.
- Kancherla D, Vattikuti S, Vippera K. Pneumatosis cystoides intestinalis: is surgery always indicated? *Cleve Clin J Med.* 2015;82:151–2.
- Ezuka A, Kawana K, Nagase H, Takahashi H, Nakajima A. Improvement of pneumatosis cystoides intestinalis after steroid tapering in a patient with bronchial asthma: a case report. *J Med Case Rep.* 2013;7:163.
- Rachapalli V, Chaluvashetty SB. Pneumatosis cystoides intestinalis. *J Clin Diagn Res.* 2017;11:TJ01–2.
- Nakatani K, Kato T, Okada S, Matsumoto R, Nishida K, Komuro H, et al. Successful treatment with hyperbaric oxygen therapy for pneumatosis cystoides intestinalis as a complication of granulomatosis with polyangiitis: a case report. *J Med Case Rep.* 2017;11:263.