



Journal of Coloproctology

www.jcol.org.br



Original Article

Repair of the middle and posterior compartments of the pelvic floor via perineal and vaginal routes without the use of mesh - technique description and case series



Raquel Ferreira Nogueira *, Renata Soares Paolinelli Botinha Macedo, Sinara Mônica de Oliveira Leite

Hospital Governador Israel Pinheiro, Belo Horizonte, MG, Brazil

ARTICLE INFO

Article history:

Received 10 May 2020

Accepted 11 July 2020

Available online 17 September 2020

Keywords:

Rectocele

Pelvic floor descent

Transperineal surgery

Transvaginal surgery

Pelvic organ prolapse

ABSTRACT

Introduction: Currently, problems such as constipation due to outlet obstruction, rectal/vaginal prolapse and fecal and urinary incontinence have become increasingly more frequent because of the population aging process, with great impact on the quality of life. **Objective:** To describe a technique for surgical repair of middle/posterior pelvic floor compartments and extra-mucosal rectal wall treatment by transperineal and vaginal approach, using native tissues and present the results in twenty patients submitted to this surgical technique.

Method: Patients with symptoms secondary to middle/posterior pelvic floor descent and anatomical changes confirmed by proctological exam and pelvic MRI defecography. Results were evaluated through the Agachan constipation score, using pre- and post-operative questionnaires.

Results: Immediate repair of rectocele and musculature, with prompt improvement of constipation, sustained by 42 months. There were no severe complications in the postoperative period.

Conclusion: This is an effective technique, with adequate anatomic repair, improvement of constipation scores and with low risk.

© 2020 Sociedade Brasileira de Coloproctologia. Published by Elsevier Editora Ltda. This is an open access article under the CC BY-NC-ND license (<http://creativecommons.org/licenses/by-nc-nd/4.0/>).

* Corresponding author.

E-mail: raquelfnogueira140@gmail.com (R.F. Nogueira).

<https://doi.org/10.1016/j.jcol.2020.07.008>

2237-9363/© 2020 Sociedade Brasileira de Coloproctologia. Published by Elsevier Editora Ltda. This is an open access article under the CC BY-NC-ND license (<http://creativecommons.org/licenses/by-nc-nd/4.0/>).

Correção dos compartimentos médio e posterior do assoalho pélvico por vias perineal e vaginal sem uso de tela – descrição de técnica e série de casos

R E S U M O

Palavras-chave:

Retocele
Descenso de assoalho pélvico
Cirurgia transperineal
Cirurgia transvaginal
Prolapso de órgãos pélvicos

Introdução: Problemas como constipação intestinal por obstrução de saída, prolapsos retal/vaginal e incontinências fecal e urinária são cada vez mais frequentes pelo envelhecimento populacional, com grande impacto na qualidade de vida.

Objetivo: Descrever técnica para correção do compartimento médio/posterior do assoalho pélvico e tratamento extramucoso da parede retal, por vias perineal e vaginal, utilizando tecidos nativos. Apresentar os resultados da cirurgia em 20 pacientes submetidas à técnica.

Método: Pacientes com sintomas secundários ao descenso de assoalho pélvico médio/posterior, submetidas à propedêutica – exame proctológico e defecografia por RNM de pelve que confirmaram as alterações anatômicas. A avaliação dos resultados foi feita com questionários no pré e pós-operatório, com a utilização do escore de Agachan para constipação intestinal.

Resultado: Correção imediata da retocele e da musculatura, com melhora imediata da constipação intestinal, sustentada ao longo de 42 meses. Sem complicações graves no pós-operatório.

Conclusão: Técnica eficaz, com correção anatômica adequada, associada a melhora significativa dos escores de constipação e de baixo risco.

© 2020 Sociedade Brasileira de Coloproctologia. Publicado por Elsevier Editora Ltda. Este é um artigo Open Access sob uma licença CC BY-NC-ND (<http://creativecommons.org/licenses/by-nc-nd/4.0/>).

Introduction

Pelvic floor disorders have become increasingly common in recent years. Greater longevity and the search for a better quality of life in a population that remains active for longer leads to the search for more effective treatments for these problems, which have a major negative impact on this quality.¹⁻³

There are several factors related to aging that worsen the evacuation functions: deterioration of the muscles, inadequate diet, physical inactivity, alteration in peristalsis caused by several diseases (neurological, diabetes, menopause, for instance) and several medications (commonly used at this age). The obstetric history, with late and prolonged births and previous pelvic surgeries, such as hysterectomy, aggravate the problem.⁴

The patients report that the stool reaches the anus, but they are unable to eliminate it, requiring much effort. As a result, anal problems such as hemorrhoids and fissures worsen, as well as rectal intussusception and, ultimately, prolapse of pelvic organs.⁴

Pelvic floor dysfunction is a complex condition. This muscle-ligament structure divided into three compartments – anterior (bladder and urethra), middle (uterus and vagina) and posterior (rectum) – must be understood as a unit. Although the symptoms are varied, affecting one compartment more significantly than the others, the diagnosis should be made by studying all three compartments, in addition to considering the clinical conditions of each patient.⁵ This variability makes it difficult to standardize the conduct, requiring knowledge and experience for an appropriate decision.

The technique that will be described applies to the treatment of patients with ruptures in the middle/posterior compartments of the pelvic floor, with laceration of the perineal fascia and fascia propria recti, which causes dilation of the rectal ampulla with the formation of rectocele and rectal intussusception. It also allows the association of small enterocele repair, vaginal dome prolapse, rupture of the perineal body and orifice procedures, such as rectal mucosal prolapse repair, hemorrhoidectomy and sphincteroplasty.

This study is about the anatomical repair of defects, via perineal and vaginal routes, using native tissues, without mesh use. Detailed surgical planning, based on findings of physical and imaging exams, is crucial for a successful treatment.

Methods

This study was an observational, descriptive and retrospective analysis carried out with 20 women presenting symptomatic rectocele (intestinal constipation with defecation effort and perianal use of fingers to aid in the removal of stool) and other anal problems (such as mucosal prolapse, hemorrhoids, anal fissure) from June 2015 to March 2020. All patients underwent repair of the middle/posterior compartments of the pelvic floor via perineal and vaginal routes, as described below. The patients answered a standardized questionnaire, based on the Agachan⁶ constipation score applied preoperatively, one year after the procedure and at the present time, by telephone interview.

The diagnosis was attained in all patients via proctological examination and defecography by magnetic resonance

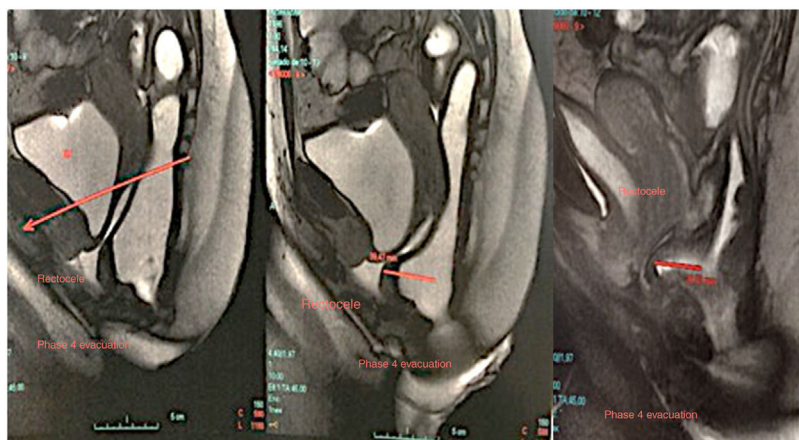


Fig. 1 – Pelvic MRI defecography showing a rectocele during the evacuation phase.

imaging of the pelvis (Fig. 1). Patients who met the criteria for colorectal cancer prevention underwent a colonoscopy.

Inclusion and exclusion criteria

All patients with symptoms of obstructed defecation, including those submitted to vaginal, perianal or anal surgeries or some type of abdominal surgery to treat pelvic floor descent, such as cystopexy or rectopexy, were included. The patients who did not agree to participate by answering the questionnaire were excluded.

The study was approved by the institution's Research Ethics Committee and all patients signed the Free and Informed Consent form.

The SPSS software version 20.0 by IBM was used for the statistical analysis. Quantitative variables were described as mean \pm SD when there was a normal distribution or as the median when the distribution was non-normal (the distribution was verified by the Shapiro-Wilk test). Categorical variables were described through absolute frequencies and percentage. The correlation analyses of the variables were performed using Spearman's correlation when the distribution was non-normal or Pearson's correlation when the distribution was normal, verified by the Shapiro-Wilk test. The level of significance was set at 5%.

Surgical technique

During the pre-anesthetic exams, menopausal patients without hormone replacement therapy were advised to use vaginal estrogen for 6 weeks (with the gynecologist's approval).

The preoperative preparation included fasting and retrograde preparation of the rectum, with a small enema on the morning of the surgery. Ceftriaxone and metronidazole were used as prophylactic antibiotics at the operating table. The anesthesia consisted of a regional anesthetic block associated with intravenous sedation. The surgery is performed in the lithotomy position. A long-term indwelling urinary catheters was used.

Surgery is started by an inverted "T" incision, with a transversal perineal incision (just anterior to the anal

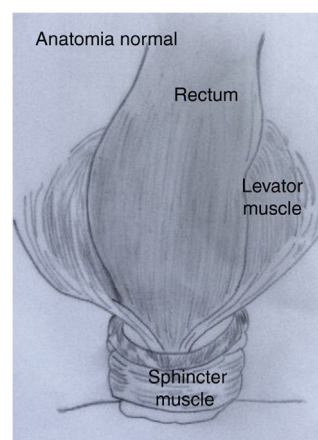


Fig. 2 – Normal anatomy.

sphincter), horizontal measuring 4–5 cm and longitudinal –colpoperineotomy – in the middle of this incision, towards the midline on the posterior vaginal wall. This second incision is performed progressively, while releasing the anterior wall of the rectum from the posterior vaginal wall, always adhered to a varying degree depending on previous obstetric/surgical trauma. This dissection is performed with a concomitant rectal examination to ensure that the surgical plan be maintained without injuring the rectal wall, which is often very thin, as well as the vaginal wall in elderly patients. The cranial limit of the colpotomy was approximately 4 – 5 cm below the cervix or the closed vaginal apex. Then, the rectal dissection begins laterally, from the perineal body to the cranial limit (bottom of the Douglas pouch). The lateral limit is the observation of the tendinous arch of the pelvis, where the levator ani muscles are inserted. It is a careful dissection, with careful hemostasis, which has variable degrees of difficulty, due to previous local trauma. At the end of the dissection, the middle-distal rectum is mobilized anteriorly and laterally (Figs. 2–4). After this release, it is easy to identify the fascia propria recti on the sides and its medial mobilization occurs without tension, correcting the trauma that occurred. Then, the extra mucosal rectal wall and the fascia propria recti are plicated, from caudal

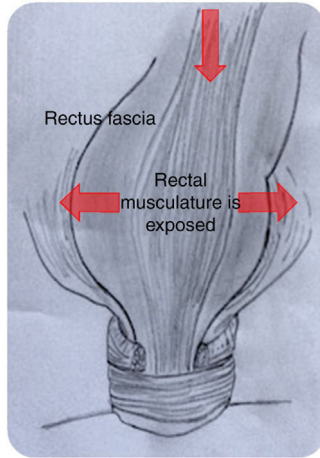


Fig. 3 – Post-trauma: laceration of the rectus fascia. Due to the trauma, the rectus fascia and recto-vaginal fascia are injured. The rectum widens, occupying the pelvis (rectocele) and descends (favoring intussusception) - arrows.

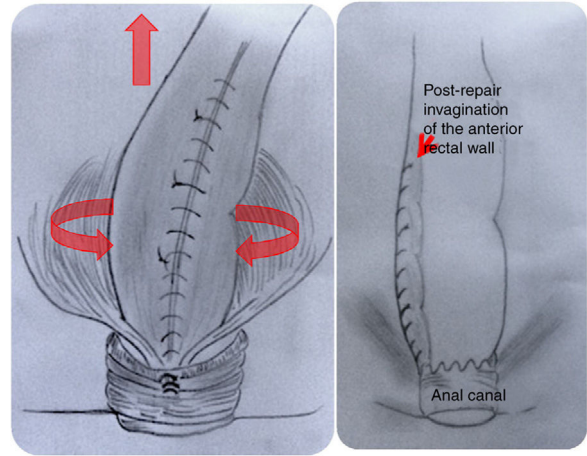


Fig. 5 – Post-repair of the fascial and sphincter rectocele defect and elongation of the rectal wall (reducing the possibility of intussusception) - arrows.

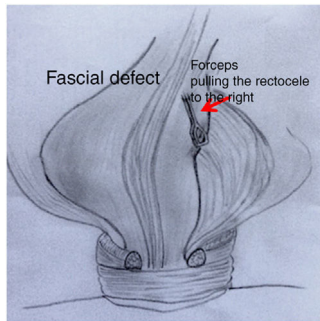


Fig. 4 – Post-dissection of the rectum latero-cranially to the left.

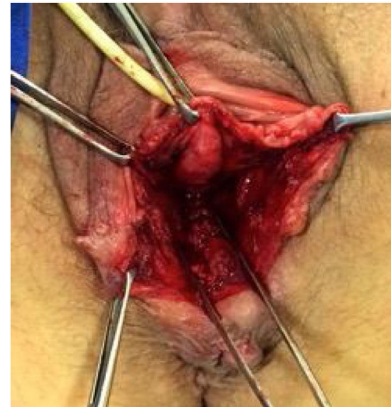

Fig. 6 – Complete plication of the anterior wall of the rectum, with rectocele repair.

to cranial to the bottom of the Douglas pouch, with separated polyglactin 2-0 sutures in “X” (Figs. 5 and 6). As the plication is performed, it can be observed that the rectovaginal fascia and the levator ani muscles approach the midline, naturally. If necessary, the peritoneum is opened at the bottom of the Douglas pouch and plicated, reducing it. Afterwards, the closing of the posterior vaginal wall begins at the apex of its opening, from cranial to caudal, with continuous sutures using 2-0 catgut, interrupted every 3 cm. This step is important, because if that is left to be closed after the rectovaginal fascia repair and the approximation of the musculature, the access becomes difficult. The rectovaginal fascia is then identified and plicated using continuous polyglactin 2-0 sutures. Then, the puborectalis muscles are plicated if there is no tension in the midline (Fig. 7). If there is tension, it is better not to perform the approximation. The posterior vaginal wall is progressively sutured. Finally, the perineal musculature is repaired *en bloc*. Then, the sphincter musculature is observed, and its repair is assessed, with the fixation of the external sphincter to the perineal body – the normal site of its insertion. The vaginal and perineal closure is completed. Then, it is already possible to observe the complete repair of the rectocele and the perineal muscle mass, as well as the reduction of hem-

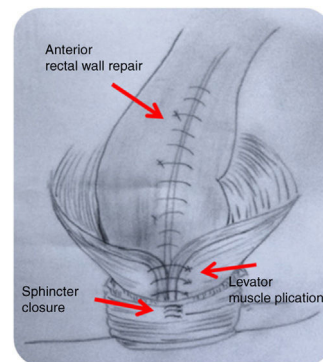


Fig. 7 – Plication of the levator muscles.

orrhoidal or rectal mucosal prolapse. If this prolapse exists, it is possible to correct it, removing only that which prolapses. At the end, a vaginal examination is performed, making it possible to observe the horizontalization of the vagina and its elongation. At the rectal examination, there is no more rec-

tocele and a longitudinal invagination on the anterior wall of the rectum, measuring approximately 8–10 cm long, can be observed, being the result of the extra mucosal plication performed. At three months postoperatively, this invagination becomes imperceptible. A compression dressing is positioned using a vaginal plug with gauze dressings embedded in xylocaine gel. The average surgery time is 120 min.

A free diet is allowed in the postoperative period, and analgesics are prescribed. On the following day, the dressing and in-dwelling catheter are removed; ambulation is permitted, and diuresis and the presence of bleeding are verified. Discharge occurs on the 2nd POD with dietary advice to avoid constipation. Normal hygiene during shower is recommended, as well as avoiding carrying weight, squatting and sexual intercourse for 30 – 40 days, depending on the patient's healing status.

Results

During this period, 20 patients aged between 37 and 81 years (mean 63.9 years) who had classic symptoms of obstructed defecation underwent surgery. As for the diet, 19 of the 20 patients declared a daily fiber intake and 40% ingested less than 1200 mL of water a day. Only one patient was nulligesta and 5 patients (20%) did not have a vaginal delivery, with an average of 3 deliveries per patient. Regarding previous surgeries, one third of the patients had already undergone hysterectomy, 10% had undergone hemorrhoidectomy and 35% had undergone a perineoplasty. Only 3 of the patients had undergone more than one procedure, namely perineoplasty and hysterectomy, and 12 patients had not undergone any surgery in the perineal region (Table 1).

There were no complications in the immediate postoperative period. Only one patient had a rectovaginal fistula on the 8th postoperative day, which resolved spontaneously up to the 30th postoperative day. Partial dehiscence of the perineal closure was common (5 patients), with healing by second intention. Two patients died in the period due to comorbidities not associated with the surgery (1 and 4 years after the surgical procedure).

All patients submitted to the questionnaire in the preoperative and postoperative period in 1 year showed improvement in the Agachan score, with a significant decrease in the mean value ($p < 0.00001$). All of them answered they would undergo the surgery again, if necessary, and were satisfied with the results. Of the 13 patients who answered the current assessment, when asked how they felt – worse, the same or better – at the current time compared to the postoperative period, 11 reported feeling better and 2 reported feeling the same, the latter due to the need to still use laxative medication to maintain good evacuation habits.

Twelve patients had the Agachan score established preoperatively – the minimum value was 5 and the maximum value was 21, with an average of 12.67. These patients, at 1 year postoperatively, had an average Agachan score of 6.75 with $p < 0.001$ (minimum values of 1 and maximum of 12). Thirteen patients answered the current questionnaire and had an Agachan score ranging from 0 to 15, with a mean value of 6.65

Table 1 – Characterization of patients.

Variables	n = 20
POD in months, median (Q1; Q3)	42.00 (21.00; 51.00)
Age (mean \pm SD)	63.86 \pm 11.10
Consumption of glasses of water, n (%)	
1 to 3	4 (20.0)
4 to 6	4 (20.0)
> 6	12 (60.0)
Frequency of fiber consumption	
2 \times a week	1 (5.0)
Daily	19 (95.0)
Pregnancies/Deliveries per patient, median (Q1; Q3)	3.00 (2.00; 4.00)
Vaginal deliveries per patient, median (Q1; Q3)	2.00 (0.50; 3.50)
Caesarean deliveries per patient, median (Q1; Q3)	0.00 (0.00; 1.00)
Hysterectomy	
Yes	6 (30.0%)
No	14 (70.0%)
Hemorrhoidectomy	
Yes	2 (10.0%)
No	18 (90.0%)
Perineoplasty	
Yes	7 (35.0%)
No	13 (65.0%)
Preoperative Agachan (mean \pm SD)	12.67 \pm 4.38
Postoperative Agachan score, 1 year (mean \pm SD)	6.70 \pm 4.24
Current postoperative Agachan score (mean \pm SD)	6.65 \pm 4.39
Surgical result: the same, better or worse	
The same	2 (15.4%)
Better	11 (84.6%)
Total	13 (100.0)

and a median (Q1; Q3) of 6.00 (2.00; 10.00), correlating with the postoperative Agachan at 1 year.

Only 33% of patients had an Agachan score ≤ 10 preoperatively, while 80% of patients had Agachan < 10 postoperatively (one year or current). The higher Agachan score in the preoperative period was associated with a higher score in the postoperative period.

Discussion

Disorders of the middle/posterior pelvic floor are complex, and it is difficult to correlate the symptoms (incomplete evacuation, fecal impaction, use of fingers to aid in the removal of stool and defecation effort) and the associated anatomical defects. Grimes et al.⁴ compared the surgical repair of the vaginal posterior wall prolapse associated or not with other pelvic procedures and concluded that this anatomical repair of the posterior compartment significantly improved all symptoms associated with evacuation difficulties, including fecal incontinence. In the study, 40% of the patients had previous pelvic surgery and 59% of them reported at least some symptom of obstructed defecation.⁴ In the present study, the mean age of the patients was 63.8 years. Fifteen patients (75%) had vaginal deliveries, with an average of 3 deliveries/patient. Six patients

Table 2 – Correlation between number of pregnancies, vaginal deliveries, age and postoperative Agachan score with the preoperative Agachan score.

Variables	Coefficient of correlation	p-value
Age	-0.238	0.456 ^a
Pregnancies	-0.428	0.165 ^b
Vaginal deliveries	-0.350	0.264 ^b
Postoperative Agachan score	0.715	0.009 ^a

^a Pearson's correlation.
^b Spearman's correlation.

Table 3 – Comparison of the means of preoperative Agachan and 1-year postoperative Agachan scores.

Preoperative Agachan (mean ± SD)	1-year postoperative Agachan score (mean ± SD)	p-value ^a
12.67 ± 4.38	6.75 ± 3.194	< 0.001

^a Paired t-test.

had a previous hysterectomy and 1/3 had already undergone a perineoplasty.

The Agachan score assesses constipation – evacuation frequency, difficulty during evacuation, feeling of incomplete evacuation, abdominal pain, time needed to evacuate, use of laxatives or use of fingers to aid in the removal of stool, frequency of failure, history of constipation in time of symptom (years). The higher the score, the worse the clinical picture (from 0 to 30).⁶ In this study, the preoperative Agachan score ranged from 5 to 21 (mean 12.67) and in the postoperative period (1 year), the mean Agachan score was 6.75 with $p < 0.001$ (minimum of 1; maximum of 12) (Tables 2 and 3). The current Agachan remains equivalent to that of 1 year – mean = 6.65 – confirming that the treatment result was maintained throughout the period (42 months of mean follow-up).

Abendstein et al.⁵ recommend a comprehensive evaluation of structures through imaging examination. In this study, in addition to the detailed proctological examination (at rest and dynamic), the patients underwent defecography by magnetic resonance imaging of the pelvis. At the time of the surgery, after anesthesia and positioning of the patient, a careful examination was once again performed, and the surgical planning was confirmed. The technique must be individualized according to the anatomical alteration.

The foundation of the described technique respects the principle of trauma surgery: restoring anatomical integrity. The damage is identified, the structures are dissected to identify them, and they are reconstructed in planes until complete repair, using native tissues. If there is no tissue avulsion, there is no reason for flap rotation. The tissues are all there, albeit sectioned and healed erroneously. "Repair the structure and you will correct the dysfunction".^{7,8}

In a Cochrane review, the transvaginal repair was considered the most effective technique to prevent prolapse recurrence, when compared to the transanal repair, both in objective and subjective indexes.⁹ A recent systematic review, after reviewing studies that included six different surgical techniques (abdominal, vaginal and trans-anal ones)

concluded that "for women with rectocele and symptoms of obstructed defecation, who require surgery, a transvaginal posterior colporrhaphy with native tissues should be considered the first approach to improve the anatomy and symptoms, despite the greater risk of dyspareunia when compared to other techniques".¹⁰ The differential of the technique we have described herein, when compared to those previously described, mainly for rectocele repair, is the lateral and cranial rectal dissection, with extra mucosal repair of the rectum and its elongation and luminal reduction, thus correcting the intussusception and prolapse (after all, the damage is extramucosal and therefore the repair must also be). A specific repair of the rectum is performed, with better reconstruction of its anatomy. The assumption is that the prolapse of the posterior vaginal wall is a consequence of the rectal pouch that is formed by the rupture of the supporting structures and repeated defecation efforts, with increased pressure in the rectal ampulla. Correcting only the vaginal wall does not adequately correct this enlargement of the rectal ampulla. As for the levator plication – only performed when the muscles naturally approach the midline after the rectal plication – it improves the functional outcome and the risk of dyspareunia should be discussed with the patients.^{11,12} Jha and Gray performed a systematic review and meta-analysis focusing on dyspareunia associated to transvaginal repair. They concluded that the sexual function is significantly improved, and dyspareunia is reduced after the surgery.¹³

This described technique does not repair the anterior compartment. Thus, urinary incontinence may appear again, after the exit is no longer obstructed due to the middle/posterior repair. Hafidh et al. found an incidence of 4% and better prospective studies are necessary to assess this topic.¹⁴

Bladder retention, fecal urgency and /or incontinence and partial dehiscence of the perineal wound may occur in the postoperative period. In the present study, there were no complications that required the patients to return to the operating room. The benefit regarding the defecation act, without the need for effort or using the fingers to aid the defecation, was observed as early as in the first evacuation.

The problem with using native tissues is the risk of recurrence. Oversand et al. found a subjective satisfaction rate of 94% in one year, with a reoperation rate of 2.6% in 5 years.¹⁵ In the 1990s, the use of transvaginal meshes to correct the prolapse of pelvic organs began to reduce recurrences. However, due to the numerous adverse events associated with this procedure, in 2019 the FDA (Food and Drug Administration) banned the sale and distribution of mesh for transvaginal surgical repair.¹⁶⁻¹⁸ We chose to use native tissues for the perineal / vaginal access procedure. We believe that the longitudinal repair of the anterior rectal wall reduces the rectal ampulla and corrects the frequently associated rectal intussusception, with a consequent improvement in evacuation – a fact confirmed by the significantly better Agachan scores in the postoperative period. Associated with perineoplasty, this rectal repair can contribute to reduce symptom recurrence.

This study has limitations: the variability of defects identified in the patients, their subjectivity when answering the questionnaires, the fact that it is a retrospective study and it was performed by a single group. Functional problems, such as constipation, are caused by factors that are not only mechan-

ical, but also neurofunctional and this makes it difficult to actually evaluate the results. We did not compare the standard colpoperineoplasty with that associated with rectal wall plication, as we believe there is greater effectiveness with rectal repair – which is what we do. The comparison of the periods before and after the surgical procedure in the same patient, considering that the treatment goal is to improve quality of life, makes us value the results, as this improvement was reported by the patients, with results being sustained throughout 42 months. A greater understanding of the problem will allow a better evaluation in future studies, which are necessary.

Conclusion

The repair of the middle / posterior compartments of the pelvic floor via perineal and vaginal routes without the use of a mesh, with associated plication of the rectal wall, is adequate for the treatment of obstructed defecation disorder caused by rectocele, with low risk.

Conflicts of interest

The authors declare no conflicts of interest.

REFERENCES

1. Cesar MAP, Leite JM, Muniz RCC, Ortiz JA. Distúrbios evacuatórios em primigestas após parto normal: estudo clínico. *Rev Bras Coloproctol*. 2011;31:126–30.
2. Rogers RG, Leeman LM, Migliocci L, Albers LL. Does the severity of spontaneous genital tract trauma affect postpartum pelvic floor function? *Int Urogynecol J Pelvic Floor Dysfunct*. 2008;19:429–35.
3. Wu JM, Vaughan CP, Goode PS, et al. Prevalence and trends of symptomatic pelvic floor disorders in U.S. women. *Obstet Gynecol*. 2014;123:141–8.
4. Grimes CL, Overholser RH, XU R, et al. Measuring the impact of a posterior compartment procedure on symptoms of obstructed defecation and posterior vaginal compartment anatomy. *Int Urogynecol J*. 2016;27:1817–23.
5. Abendstein B, Petros PEP, Richardson PA, et al. The surgical anatomy of rectocele and anterior rectal wall intussusception. *Int Urogynecol J*. 2008;19:705–10.
6. Agachan F, Chen T, Pfeifer J, Reissman P, Wexner SD. A constipation scoring system to simplify evaluation and management of constipated patients. *Dis Colon Rectum*. 1996;39:681–5.
7. Petros PEP, Woodman PJ. The integral theory of continence. *Int Urogynecol J*. 2008;19:35–40.
8. Nichols DH, Randall CL. *Posterior colporrhaphy and perineorrhaphy, in vaginal surgery*. 4th ed Baltimore, U.S.A: Williams & Wilkins; 1996. p. 257–89.
9. Mowat A, Maher D, Baessler K, Christmann-Schmid C, Haya N, Maher C. Surgery for women with posterior compartment prolapse. *Cochrane Database of Systematic Reviews*, Oxford, v. 3, n. 3, CD012975; 2018, <http://dx.doi.org/10.1002/14651858.CD012975>.
10. Grimes CL, Schimpf MO, Wieslander CK, Sleemi A, Doyle P, You W, et al. Surgical interventions for posterior compartment prolapse and obstructed defecation symptoms: a systematic review with clinical practice recommendations. *Int Urogynecol J*. 2019;30:1433–54.
11. Farid M, Madbouly KM, Hussein A, et al. Randomized controlled trial between perineal and anal repairs of rectocele in obstructed defecation. *World J Surg*. 2010;34:822–9.
12. Maher C, Feiner B, Baessler K, Schmid C, Haya N, Brown J. Surgery for women with anterior compartment prolapse. *Cochrane Database Syst Rev*. 2016;11:CD004014.
13. Jha S, Gray T. A systematic review and meta-analysis of the impact of native tissue repair for pelvic organ prolapse on sexual function. *Int Urogynecol J*. 2015;26:321–7.
14. Hafidh BA, Chou Q, Khalil MM, et al. De novo stress urinary incontinence after vaginal repair for pelvic organ prolapse: one-year follow-up. *Eur J of Obstet Gynecol and Reproduct Biology*. 2013;168:227–30.
15. Oversand SH, Staff AC, Spydslaug AE, et al. Long-term follow-up after native tissue repair for pelvic organ prolapse. *Int Urogynecol J*. 2014;25:81–9.
16. Murphy M, Holzberg A, Raalte H, et al. Time to rethink: an evidence-based response from pelvic surgeons to the FDA Safety Communication: “UPDATE on Serious Complications Associated with Transvaginal Placement of Surgical Mesh for Pelvic Organ Prolapse”. *Int Urogynecol J*. 2012;23:5–9.
17. FDA. U.S. Food and Drug Administration. Medical devices. FDA strengthens requirements for surgical mesh for the transvaginal repair of pelvic organ prolapse to address safety risks. FDA’s role and activities. Disponível em: <https://www.fda.gov/newsevents/newsroom/pressannouncements/ucm479732.htm>. Acesso em: 24 Apr. 2020.
18. FDA. U.S. Food and Drug Administration. Medical devices. FDA Urogynecologic surgical mesh implants. Disponível em: <https://www.fda.gov/medical-devices/implants-and-prosthetics/urogynecologic-surgical-mesh-implants>. Acesso em: 24 Apr. 2020.